

---

# The effect of platelet-rich plasma on female androgenetic alopecia: A randomized controlled trial



Danielle P. Dubin, MD,<sup>a</sup> Matthew J. Lin, MD,<sup>a</sup> Hayley M. Leight, MD,<sup>a</sup> Aaron S. Farberg, MD,<sup>a,b</sup> Richard L. Torbeck, MD,<sup>a</sup> William B. Burton, PhD,<sup>c</sup> and Hooman Khorasani, MD<sup>a</sup>  
*New York and Bronx, New York and Little Rock, Arkansas*

**Background:** Platelet-rich plasma (PRP) may be a useful treatment for androgenetic alopecia (AGA), although objective studies are needed.

**Objective:** To determine whether PRP injections improve female AGA.

**Method:** Prospective randomized controlled trial of 30 women diagnosed with AGA. Patients received subdermal scalp injections of Eclipse system PRP or placebo saline at weeks 0, 4, and 8. Outcome measures were changes in hair density (hair/cm<sup>2</sup>), hair caliber (mm), and blinded global photographic assessment (improved or not improved) at week 24.

**Results:** Blinded global photographic assessment indicated that 57% of patients receiving PRP versus 7% of patients receiving saline improved at week 24 from baseline ( $P < .01$ ). Compared to baseline, there was improvement in mean density in the PRP group versus the placebo group at week 8 (+71.1 vs -26.7 hairs/cm<sup>2</sup>;  $P < .01$ ) and week 24 (+105.9 vs -52.4 hairs/cm<sup>2</sup>;  $P < .01$ ). Compared to baseline, there was improvement in mean caliber in the PRP group versus the placebo group at week 8 (+0.0043 vs -0.0034 mm;  $P < .01$ ) and week 24 (+0.0053 vs -0.0060 mm;  $P < .01$ ). Adverse effects included headache, scalp tightness, swelling, redness, and postinjection bleeding.

**Limitations:** Two patients lost to follow-up.

**Conclusions:** PRP with the Eclipse system is a safe and effective intervention for female AGA. (J Am Acad Dermatol 2020;83:1294-7.)

**Key words:** androgenetic alopecia; female pattern hair loss; platelet-rich plasma; regenerative medicine.

Androgenic alopecia (AGA) is the most common form of alopecia, affecting approximately half of all women over their lifetime.<sup>1,2</sup> Most affected female patients are relatively young, and many studies have shown the deleterious psychological and social impact of this condition.<sup>3,4</sup> This study aimed to evaluate the efficacy of monthly interval platelet-rich plasma (PRP) monotherapy for female AGA.

## METHODS

### Study design

Institutional review board approval was obtained. Thirty women were enrolled and randomized into a treatment group (15 patients receiving PRP injections at weeks 0, 4, and 8) or control group (15 patients receiving saline injections at weeks 0, 4, and 8) by using block randomization. The final evaluation occurred at week 24. All patients were recruited in

---

From the Department of Dermatology, Icahn School of Medicine at Mount Sinai, New York<sup>a</sup>; Arkansas Dermatology, Little Rock<sup>b</sup>; and Albert Einstein College of Medicine, Bronx.<sup>c</sup>

Funding sources: Supported by Eclipse Aesthetics, LLC [Icahn School of Medicine at Mount Sinai Grants and Contracts Office no. 18-1714(0001)].

Disclosure: Dr Farberg currently serves on the advisory board of Suneva Medical, Inc. Drs Dubin, Lin, Leight, Torbeck, Burton, and Khorasani have no conflicts of interest to declare.

IRB approval status: Reviewed and approved by the IRB of the Mount Sinai School of Medicine (Human Subject no. 18-00427).

---

Accepted for publication June 27, 2020.

Correspondence to: Danielle P. Dubin, MD, Department of Dermatology, Icahn School of Medicine at Mount Sinai, 234 East 85th St, 5th Floor, New York, NY, 10028. E-mail: [DPDubin121@gmail.com](mailto:DPDubin121@gmail.com).

Published online July 7, 2020.

0190-9622/\$36.00

© 2020 by the American Academy of Dermatology, Inc.

<https://doi.org/10.1016/j.jaad.2020.06.1021>

August 2018 from the Mount Sinai Department of Dermatology in New York, NY.

### Participation

All participants required a medical diagnosis of AGA as the sole cause of their hair loss (Ludwig I-III, where I is appreciable thinning of the crown hair, II is increased territorial involvement and scalp visibility, and III is total denudation of the areas involved in I and II).<sup>5</sup> Exclusion criteria included the use of minoxidil, finasteride, or spironolactone within the prior 12 months and for the duration of the study. Other exclusion criteria included other causes of alopecia and abnormal ferritin levels, thyroid stimulating hormone levels, or platelet counts within the 6 months before enrollment.

### Interventions

At each visit, participants were blinded to the intervention received. After providing informed consent, participants entered a single clinic room with a single investigator who blindfolded the participants and performed all interventions. Topical or injected local anesthetic was not used in either group.

For the 15 participants in the treatment group, 22 mL of whole blood was drawn from the antecubital fossa using a sterile needle. The study investigator left the room for 25 minutes and prepared the PRP in a separate location. The PRP was prepared in a standardized fashion using the Eclipse PRP system (Eclipse Aesthetics LLC, Dallas, TX). The blood was centrifuged at 3500 revolutions per minute for 10 minutes, yielding a red blood cell precipitate and plasma supernatant. The uppermost portion of the supernatant fluid containing the platelet-poor plasma was then removed (approximately 5.0 mL). The remaining 4.0 mL of supernatant was gently inverted in the vacutainer 7 times to resuspend the platelets within the plasma. The PRP was then drawn up into multiple 1.0-mL Luer lock syringes.

The scalp was cleansed topically with chlorhexidine gluconate solution 4.0% weight/volume. Then, 4.0 mL of PRP was then injected 3 to 8 mm below the skin surface into the subdermal plane via a 30-gauge 0.5-inch needle. The subdermal technique was selected based on methods outlined in prior PRP studies.<sup>1,6</sup> Each injection was made up of 0.2 mL of

PRP and spaced 1 to 2 cm apart. The injection pattern consisted of a ring around the scalp followed by a pass down the midline (Fig 1). The patients remained blindfolded throughout the treatment.

For participants in the placebo group, the same preparation and injection protocol was reproduced with 4.0 mL of saline.

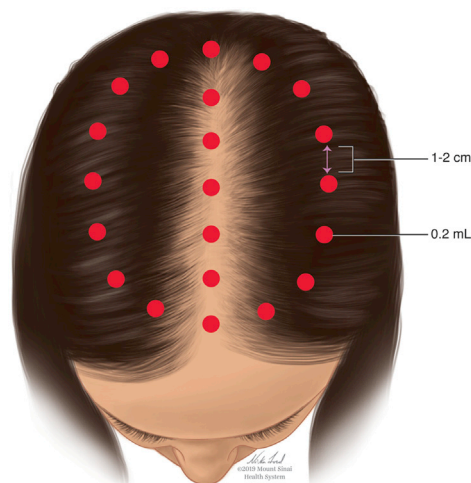
Patients were instructed to abstain from washing their hair or taking nonsteroidal anti-inflammatory drugs for 24 hours after the procedure. Patients were otherwise permitted to maintain their usual nonmedical scalp care practices.

### Data collection

Data were collected at weeks 0, 8, and 24 using global (Cyber-shot DSC-W290, Sony, Tokyo, Japan) and magnified photography ( $\times 50$  and  $\times 100$  magnification; Folliscope 2.8, Anagen, Seoul, Korea). The magnified photography evaluated mean hair density (hairs/cm<sup>2</sup>) and shaft caliber (mm). The magnified photographs were standardized between visits by using a single representative point of focus (birthmark, nevus, angioma, scar, etc) on each participant's scalp. Outcome measures were changes in hair density, caliber, and blinded global photographic assessment (improved or not improved) at weeks 8 and 24 compared to baseline. Statistical analyses were performed using SAS, version 9.4 (SAS Institute, Cary, NC).

### CAPSULE SUMMARY

- Androgenetic alopecia in female patients is common; however, effective treatments are limited. The authors investigated the efficacy of platelet-rich plasma as a monotherapy to improve hair density, hair caliber, and general hair appearance for female androgenetic alopecia.
- Platelet-rich plasma improved hair density, hair caliber, and global hair appearance compared to placebo.



**Fig 1.** Standard injection pattern for platelet-rich plasma or saline.

**Abbreviations used:**

AGA: androgenic alopecia  
PRP: platelet-rich plasma

**RESULTS**

Overall, 14 PRP group and 14 placebo group participants completed the study (Fig 2). At baseline, there were no significant differences between groups in terms of demographics, Ludwig score, hair density, or caliber (Table I).

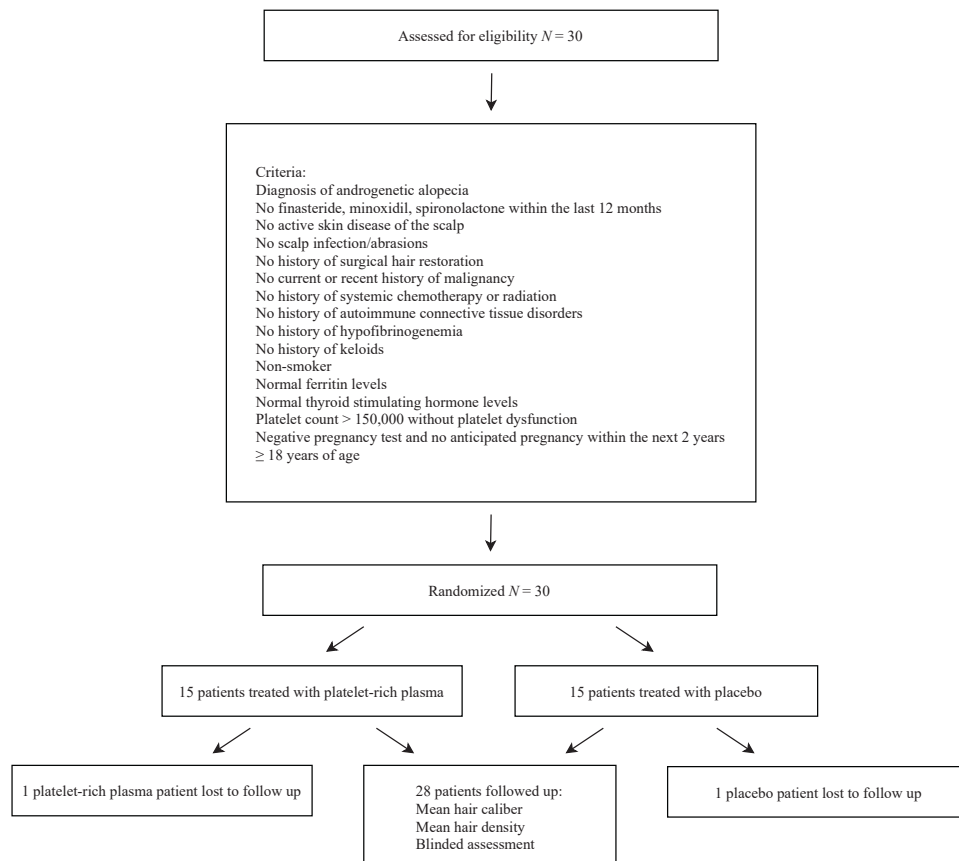
At week 8 compared to baseline, there was significant improvement in mean hair density in the PRP group versus placebo group (+71.1 vs -26.7 hairs/cm<sup>2</sup>;  $P < .01$ ). At week 24 compared to baseline, there was sustained improvement of mean hair density in the PRP group versus placebo group (+105.9 vs -52.4 hairs/cm<sup>2</sup>;  $P < .01$ ) (Fig 3). Categorical evaluation showed that 93% of participants in the PRP group had an improved hair density score at week 24 compared to baseline,

whereas 0% of participants in the saline group had an improved hair density score across that same period ( $P < .01$ ).

At week 8 compared to baseline, there was significant improvement in mean hair caliber in the PRP group versus placebo group (+0.0043 vs -0.0034 mm;  $P < .01$ ) (Fig 3). At week 24 compared to baseline, there was sustained improvement of mean hair caliber in the PRP group versus placebo group (+0.0053 vs -0.0060 mm;  $P < .01$ ). Categorical evaluation showed that 79% of patients in the PRP group had an improved hair caliber score at week 24 compared to baseline, whereas only 7% of patients in the saline group had an improved hair caliber score across that same period ( $P < .01$ ).

For the blinded global photographic assessment, 57% of PRP group patients improved from baseline (Fig 4). Only 7% of saline group patients improved from baseline ( $P < .01$ ).

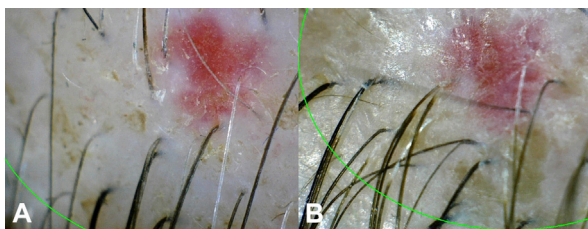
The most commonly reported adverse effect was mild headache, occurring in 50% of PRP group patients and 29% of saline group patients ( $P > .05$ ). The next most frequent adverse effect was a



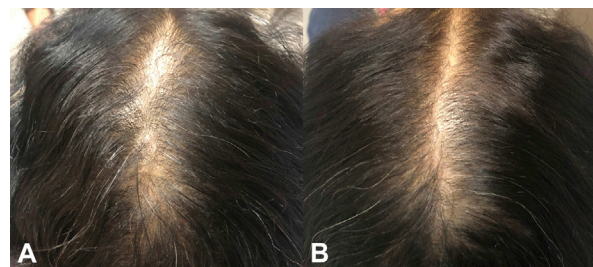
**Fig 2.** Flow diagram of the randomized controlled trial for women with androgenetic alopecia.

**Table I.** Baseline characteristics of women treated with platelet-rich plasma or placebo (N = 30)

Characteristics	Platelet-rich plasma group (n = 15)	Placebo group (n = 15)
Duration of hair loss, mo, mean (range)	67 (8-204)	93 (8-300)
Age, y, mean (range)	47 (28-70)	53 (27-85)
Race/ethnicity, n (%)		
White	8 (53)	7 (47)
Hispanic	5 (33)	7 (47)
Other	2 (13)	1 (7)
Ludwig score, n (%)		
I	8 (53)	9 (60)
II	6 (40)	5 (33)
III	1 (7)	1 (7)
Hair density, hairs/cm <sup>2</sup> , mean (range)	556 (102-830)	589 (321-807)
Hair caliber, mm, mean (range)	0.0509 (0.0300-0.0690)	0.0570 (0.0400-0.0800)



**Fig 3.** **A**, Baseline magnified scalp photograph (original magnification,  $\times 50$ ) of a representative participant. **B**, Week 24 magnified scalp photograph (original magnification,  $\times 50$ ) of the same participant who received platelet-rich plasma injections at weeks 0, 4, and 8, showing increased hair density and caliber.



**Fig 4.** **A**, Baseline clinical scalp photograph of a representative participant. **B**, Week 24 clinical scalp photograph of the same participant who received platelet-rich plasma injections at weeks 0, 4, and 8, showing improvement in global photographic assessment

sensation of scalp tightness, occurring in 50% of PRP group patients and 21% of saline group patients ( $P = .03$ ). Other adverse events occurring only in the PRP group were swelling (29%;  $P > .05$ ), redness (14%;  $P > .05$ ), postinjection bleeding (7%;  $P > .05$ ), and tingling (7%;  $P > .05$ ). All adverse effects were mild and resolved without intervention within 24 hours.

## CONCLUSION

This prospective, randomized, placebo-controlled trial provides evidence for the efficacy of monthly interval PRP with the Eclipse system to improve global hair appearance for women with AGA. Importantly, this finding was substantiated by objective improvements in hair density and caliber. Further studies will be useful to determine optimal preparation methods, scheduling, and combination therapies.

The authors acknowledge Ni-ka Ford, MS, academic medical illustrator, Instructional Technology Group, Icahn School of Medicine at Mount Sinai, New York, NY.

## REFERENCES

1. Hausauer AK, Jones DH. Evaluating the efficacy of different platelet-rich plasma regimens for management of androgenetic alopecia: a single-center, blinded, randomized clinical trial. *Dermatol Surg.* 2018;44(9):1191-1200.
2. Rogers NE, Avram MR. Medical treatments for male and female pattern hair loss. *J Am Acad Dermatol.* 2008;59(4):547-568.
3. Marks DH, Penzi LR, Ibler E, et al. The medical and psychosocial associations of alopecia: recognizing hair loss as more than a cosmetic concern. *Am J Clin Dermatol.* 2019;20(2):195-200.
4. Ahluwalia J, Fabi SG. The psychological and aesthetic impact of age-related hair changes in females. *J Cosmet Dermatol.* 2019; 18(4):1161-1169.
5. Gupta M, Mysore V. Classifications of patterned hair loss: a review. *J Cutan Aesthet Surg.* 2016;9(1):3-12.
6. Gupta AK, Cole J, Deutsch DP, et al. Platelet-rich plasma as a treatment for androgenetic alopecia. *Dermatol Surg.* 2019; 45(10):1262-1273.