

Use of autologous platelet-rich plasma in healing skin graft donor sites

Objective: To demonstrate that the use of platelet-rich plasma (PRP) enhances both the quality of healing and the time required for wound healing at a skin graft donor site.

Methods: Patients who had dermo-epidermal skin grafts taken from the thigh area were included in a prospective, randomised clinical study. PRP was applied to one donor site and then covered with Vaseline-impregnated, open-weave gauze and gauze, while the contralateral donor site on the other thigh served as a control and was covered with the open-weave gauze and gauze without PRP.

Results: A total of 24 patients took part in the study, of which three developed infections and were thus removed from the study. Use of PRP reduced the wound healing time of the dermo-epidermal graft donor

sites by a mean 17.8% and median 18 days. On average, the treated donor sites healed in 14.9 days compared with 18.4 days for the control group. The median was 14 days compared with 18 days in the control group ($p=0.026$). In one patient, healing was slower on the side where PRP was applied. In 20 patients, healing of the donor site was accelerated where PRP was applied.

Conclusion: The study demonstrated a beneficial effect of PRP, as healing time was shortened. Using PRP to heal wounds could be beneficial for patients for whom commonly available wound healing therapies have failed, as well as for high-risk patient groups for whom problematic wound healing may be expected.

Declaration of interest: The authors have no conflicts of interest.

growth factors • platelet-rich plasma • thrombocytes • wound healing

Platelet-rich plasma (PRP) is defined as an autologous blood with a higher concentration of platelets than occurs in peripheral blood.¹ In clinical practice, the optimal concentration is considered to be approximately 2.5–5 times greater than the standard concentration in peripheral blood.² PRP has been used therapeutically since the 1980s,³ in many medical areas, such as maxillofacial surgery, stomatosurgery,^{4,5} orthopaedics,⁶ aesthetic and reconstructive surgery,⁷ burns medicine and other areas of medicine.⁸

The effect of PRP is based on the vital role of platelets in haemostasis, angiogenesis, and the repair and healing of tissues. They are the first elements of the early inflammation response of the healing process.⁹ Platelets release molecules such as alpha-granules, dense granules and lysosomes, which contain a number of essential growth factors, cytokines, and signal and other factors.¹⁰ Alpha-granules, containing growth factors such as platelet-derived growth factor (PDGF), insulin-like growth factor 1 (IGF1), transforming growth factor-beta 1 (TGF- β 1), vascular endothelial growth factor (VEGF), basic fibroblastic growth factor (bFGF) and epidermal growth factor (EGF), appear to be the most important for the healing process.¹¹

Catecholamines, histamine, serotonin, dopamine and calcium ions (also contained in platelets) may play a significant role in the healing process. This mainly consists of increasing the permeability of capillaries and activating the inflammation response.¹² In order for all of these factors to be released, the platelets must be activated.¹³ Activation occurs either through adhesion to and contact with endothelium molecules or through contact with thrombin and thromboxane A₂.¹⁴ Approximately 95% of pre-synthesised growth factors are released within 10 minutes of activation of platelets and the remaining 5% are synthesised and released during their remaining lifetime (5–10 days).^{13,15}

The aim of this study is to demonstrate that the use of PRP enhances both the quality of healing and the time required for wound healing at a skin graft donor site.

Method

This prospective, randomised clinical study was conducted with patients who had undergone collection of a dermo-epidermal skin graft. The inclusion criteria were patients aged 18–95 years, with the possibility of collecting a dermo-epidermal skin graft from both legs. Exclusion criteria were American Society of Anaesthesiologists (ASA) physical status classification of four (ASA 4) and higher, patient non-adherence, patient undergoing anticoagulation therapy, and healing complicated by infection (Table 1).

Ethical approval

This study project has been approved by the Ethics Committee of the University Hospital in Hradec Kralove (reference number 201107 S44P). All patients provided written informed consent to participate in the study.

Igor Slaninka,^{1,2} MD, PhD*; Aleš Fibr,^{1,2} MD, PhD; Milan Kaška,^{1,2} MD, PhD, Associate Professor; Jiří Páral,^{1,2,3} MD, PhD, Associate Professor

*Corresponding author email: islaninka@seznam.cz

1 Department of Surgery, Faculty of Medicine of Charles University and University Hospital Hradec Králové, Czech Republic. **2** Department of Surgery, Faculty of Medicine of Charles University in Hradec Králové, Czech Republic. **3** Department of Military Surgery, Faculty of Military Health Sciences, University of Defence, Hradec Králové, Czech Republic.

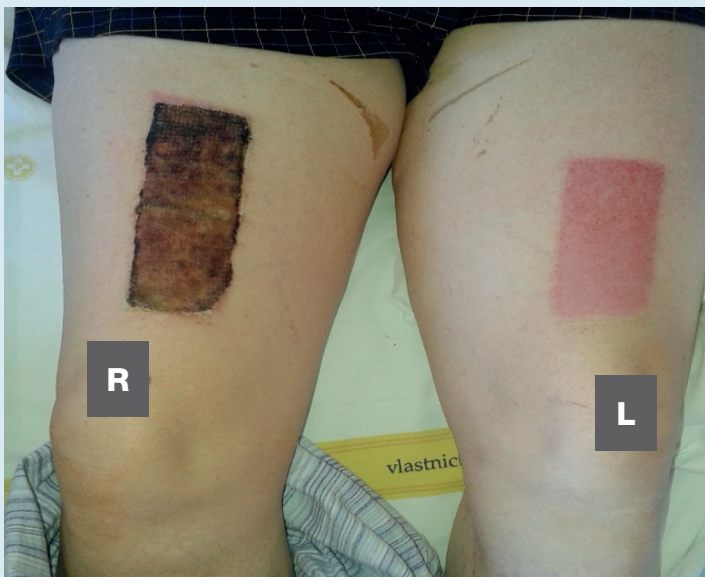
Table 1. Demographic parameters of investigated patients

| Characteristic | Gender | | |
|---|------------------------------|---------------|----|
| | Male | Female | |
| Number, n | 9 | 15 | |
| Excluded, n | 0 | 3 | |
| Mean age of those included, years (range) | 60.44 (18–91) | 70.13 (55–84) | |
| Wound aetiology | Trophic (vascular, diabetes) | 5 | 12 |
| | Trauma | 3 | 0 |
| | Burn injury | 1 | 0 |

Fig 1. Application of platelet-rich-plasma (PRP) on donor site

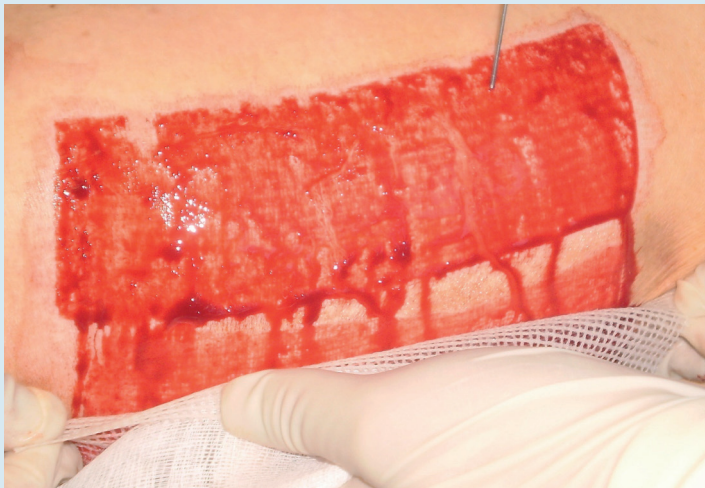

Fig 2. Patient number 21, 16 days after surgery, platelet-rich-plasma (PRP) applied on left thigh



Donor and skin graft sites

After taking a dermo-epidermal skin graft, the donor site was selected as a suitable model for examining wound healing as it constitutes a clean wound with a clearly defined depth. Collection was performed by electric dermatome (Aesculap, Aesculap Inc., B. Braun, US) on both sides at the same location, size and depth (0.2mm for all donor skin grafts).

After fulfilling the inclusion criteria, each patient underwent collection of a dermo-epidermal skin graft from each lower limb thigh region. The healing process of the donor site was supported by autologous PRP. For each patient, we used PRP on one side only and compared its speed of healing with that of the other side. The result was therefore not distorted by other factors, such as comorbidity, which could influence healing speed and often have a crucial influence on the wound healing process.

Collection of platelet-rich plasma

A test set (TropoCells, Estar Technologies Ltd., Israel) and centrifuge were used to prepare the PRP. The PRP was collected from the patient’s peripheral blood before surgery. From 10ml of venous blood 2–3ml of PRP were obtained. Venous blood was collected into a vacuum tube with anti-coagulant (adenine citrate dextrose) and separation gel (pore size 10µm). Erythrocytes, platelet-poor plasma (PPP), and platelets were separated after 10 minutes of centrifugation at 3600 revolutions/minute (RPM). Excess plasma (3ml) was collected and the remaining plasma was mixed with the platelets.

The resulting PRP was separated using a special filtration tube and evenly applied topically using a syringe onto the surface of the entire donor site (Fig 1). Upon contact with the donor site, the PRP gelled in 1–2 minutes. The gel was left to work for at least five additional minutes. The wounds on both sides were covered in the standard manner using the same number of ointment (Vaseline)-impregnated open-weave gauze (first layer) and gauze squares (second layer). The side upon which the PRP was applied was randomly selected before surgery using the envelope method. Wound dressings were regularly changed, usually every second day, sometimes more often when it was necessary, until completely healed. On the second day after surgery, the outer gauze squares were removed and only the ointment-impregnated open-weave gauze and inner square were left. Subsequent dressing changes were performed in the same manner, always replacing the outer layers of dry gauze squares.

The wounds were inspected every day and records were made in a prepared table of any seeping, presence of odour, change in surrounding skin, or loss of the covering (for example, due to falling off). Once the donor site healed, it was possible to remove the covering completely.

The day when the covering could be removed completely and a fully-healed donor site was present under the dressing was recorded precisely. Potential development of infection at the donor site, which

Table 2. Patients' individual skin donor graft healing time with and without platelet-rich-plasma (PRP)

| Patient (number) | Healing with PRP (days) | Healing without PRP (days) | Healing acceleration (%) | Days of acceleration (days) | Complication |
|--------------------|-------------------------|----------------------------|--------------------------|-----------------------------|--------------|
| 1 | 14 | 28 | 50 | 14 | No |
| 2 | 10 | 14 | 29 | 4 | No |
| 3 | 33 | 40 | 18 | 7 | No |
| 4 | 14 | 21 | 33 | 7 | No |
| 5 | 21 | 21 | 0 | 0 | No |
| 6 | 15 | 20 | 25 | 5 | No |
| 7 | 12 | 15 | 20 | 3 | No |
| 8 | 10 | 12 | 17 | 2 | No |
| 9 | 9 | 11 | 18 | 2 | No |
| 10 | 12 | 17 | 29 | 5 | No |
| 11 | 16 | 13 | -19 | -3 | No |
| 12 | 13 | 15 | 13 | 2 | No |
| 13 | 14 | 18 | 22 | 4 | No |
| 14 | 16 | 20 | 20 | 4 | No |
| 15 | 16 | 18 | 11 | 2 | No |
| 16 | 14 | 16 | 13 | 2 | No |
| 17 | 14 | 22 | 36 | 8 | No |
| 18 | 11 | 11 | 0 | 0 | No |
| 19 | 22 | 22 | 0 | 0 | No |
| 20 | 16 | 19 | 16 | 3 | No |
| 21 | 10 | 13 | 23 | 3 | No |
| 22* | 22 | 42 | 48 | 20 | Infection |
| 23* | 30 | 30 | 0 | 0 | Infection |
| 24* | 40 | 40 | 0 | 0 | Infection |
| *Excluded patients | | | | | |

would necessitate early removal of the dressing, was also monitored. If, after spontaneous removal of the dressing from the donor site (for example, if the dressing fell off), and there remained an area not covered by epithelium, two surgeons determined independently the percentage of unhealed area and the resulting percentage was the average of the two scores. The day when complete healing occurred (i.e. the donor site was completely covered with epithelium) was recorded (Fig 2). During the treatment, photo documentation was taken and continuously evaluated. Clinical evaluation was performed by surgeons who had not performed the skin-graft operation.

Statistical analysis

Results were analysed using the statistics software SigmaPlot 13.0 (SystatSoftware Inc., US). The methods

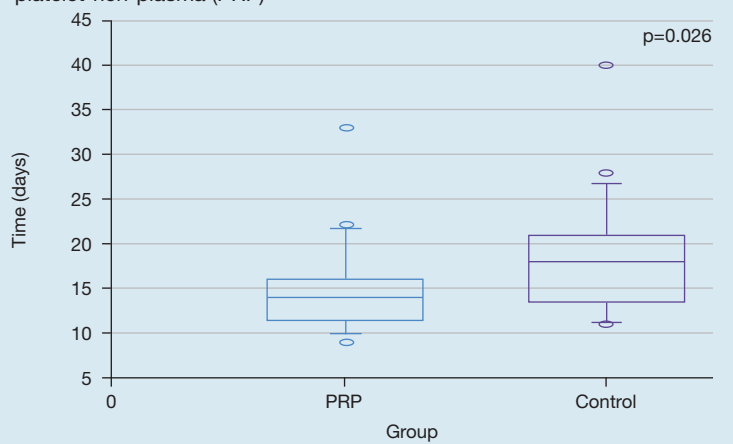
were selected by the software and parametric or non-parametric methods for one-way ANOVA (analysis of variation, Shapiro-Wilk, Kruskal-Wallis and Tukey Test). The level of statistical significance ($p \leq 0.05$) has been included.

Results

A total of 24 patients were included in the study (Table 1). Indications for performing skin autografting included burns ($n=1$), traumatic wounds ($n=3$), or hard-to-heal lower leg wounds ($n=20$). Of the total number of patients, three developed infections and were thus removed from the study (Table 2).

The results were evaluated using statistical methods (one-way analysis of variance at the $p=0.026$ level of significance). Healing of the donor site was accelerated by a mean of 17.8% (a median of 18 days). The PRP-treated

Fig 3. Time period of skin healing of donor graft with and without platelet-rich-plasma (PRP)



donor sites healed in a mean of 14.9 days, compared with a mean of 18.4 days for the non-PRP-treated control group. The median was 14 days compared with 18 days for the non-PRP-treated control group (Fig 3).

Slower healing on the side where PRP was applied (on average 16 days with PRP versus 13 days without PRP) was observed in one patient. In 17 patients, healing of the donor site was faster on the side where PRP was applied (on average 14.2 days with PRP versus 18.8 days without PRP). In three patients, healing of the donor site with PRP was the same as that of the control group (on average, 18 days for both PRP and non-PRP groups).

Discussion

There currently exists a wide range of wound treatment options such as hydrocolloids, hydrogels and alginates. In certain patient groups, wounds may not heal successfully despite treatment or may take a long time to heal. A possibility for preventing such complications is to treat the wounds using PRP. The beneficial effects of PRP on healing bone as well as soft tissues have been demonstrated in many studies.^{16–20} Similarly, a number of *in vitro* studies have demonstrated a clearly beneficial effect of PRP in the healing process.²¹ On the other hand, in some *in vivo* studies, this effect has not been clearly demonstrated.^{22,23}

A key reason for these conflicting findings that wound healing is such a complex and time-variable process, merely increasing the concentration of growth factors present does not necessarily result in faster healing even though it facilitates healing generally.¹¹ We therefore decided to test whether PRP has a beneficial effect on wound healing in a clinical study. After taking a skin graft, the donor site is a clearly defined wound. By using essentially the same wound of the same patients for the control and treatment groups, we eliminated other factors which could influence healing. According to available studies, the donor site is healed when the surface is completely re-epithelialised, there is no exudate, and no pathological scar formation.²⁴ In the evaluation of

healing, an experienced observer, as used in this study, is considered to be faster, cheaper and as efficient as a computer programme, which can be also used.^{25,26}

The established method at our facility for donor site wound healing after a dermo-epidermal graft is to apply gauze with paraffin and a sterile covering. Although some studies have confirmed that other materials such as alginates can be beneficial for patients in terms of reduced postoperative pain and increased healing speed,²⁷ other studies have shown that gauze with paraffin is not merely an effective but also a cost-effective method for healing the donor site.²⁸ This method did not allow us to apply PRP on the wound more than once. However, our study demonstrated that a one-off application is sufficient.

Every wound dressing change has also a negative impact on wound healing by:

- Possible traumatisation of soft tissues on the surface of the wound
- Decreasing the temperature of the wound tissue
- Increasing the risk of microbial contamination.

A clean donor site heals in about 10–14 days. It took 15–40 days in many of our patients, which can be explained by their higher age and wider comorbidities (Table 1).

PRP that is applied topically on the wound has a triple effect on healing. First, there are the growth factors that are stimulated and which accelerate wound healing.²⁹ Secondly, there is fibrin, which causes jellification thanks to a fibrin net and helps to stop bleeding. Finally, there is the antimicrobial effect of PRP.^{30,31}

In this study, PRP preparation took approximately 10 minutes. As this can be performed in parallel with the patient's surgery, the procedure time is therefore not extended. Application of PRP to the donor site, waiting for its jellification and allowing time for the PRP to work entails adding approximately 10 minutes to the time in surgery. Given the benefit to the patient, we regard this time factor to be acceptable.

In three patients in our study, healing was as fast for the control wound as it was for the PRP-treated wound. In one patient, the healing was actually slower where the treatment was applied. We attribute this fact to either a failure in the PRP preparation or complicated wound healing. For the patients who developed infections and had to be removed from the study, no connection was found between use of the PRP and development of the infections. All the infections first occurred on the side where PRP was not used and only subsequently (after several days) on the donor site where the PRP was used. Faster healing of the wound where PRP was used and the related lower wound secretion observed (though not formally evaluated) in comparison with the non-PRP-treated control group may be one of the reasons why infection could have developed.

Our study confirmed the beneficial effect of PRP in accelerating wound healing. Nevertheless, our results also confirm that even though PRP use accelerates the healing process, that acceleration is not sufficiently

substantial for PRP use to be the method of choice for healing wounds. We also believe that PRP use will not lead to complete elimination of complications, such as delayed healing or infections, in the wound healing process. It may nevertheless reduce such complications by accelerating wound healing.

Limitations

The main limitations of the study were its small sample size and the short length of time for follow-up of patients.

Conclusion

Use of PRP is an experimentally and clinically verified method of wound healing. Although the time factor in preparation is not negligible, considering the benefit it

may bring to patients with certain indications, PRP preparation is a viable choice for treating wounds. This was demonstrated by the results of our study. Because of the significant role of growth factors in the wound healing process, PRP use appears to be one possibility for accelerating wound healing or facilitating healing when the healing process is slowed or suspended (for example, in the case of surgical or traumatic wounds or burns). Further studies on the use of PRP in such patients may show beneficial effects.

To provide clear proof of the methodological advantages of using PRP and its introduction into everyday clinical practice, additional prospective randomised studies with higher numbers of patients will be needed. **JWC**

Acknowledgements: The article was supported by the Project of Ministry of Defence of the Czech Republic: 'A long-term organization development plan 1011' and by the grant PROGRES Q40/04 of Charles University, Prague, Czech Republic. The authors are grateful to Mr. Ian McColl, MD, PhD for correction of the text.

References

- Carter MJ, Fylling CP, Parnell LK. Use of platelet rich plasma gel on wound healing: a systematic review and meta-analysis. *Eplasty* 2011; 11:e38
- Graziani F, Ivanovski S, Cei S et al. The in vitro effect of different PRP concentrations on osteoblasts and fibroblasts. *Clin Oral Implants Res* 2006; 17(2):212–219. <https://doi.org/10.1111/j.1600-0501.2005.01203.x>
- Driver VR, Hanft J, Fylling CP, Beriou JM; Autologel Diabetic Foot Ulcer Study Group. A prospective, randomized, controlled trial of autologous platelet-rich plasma gel for the treatment of diabetic foot ulcers. *Ostomy Wound Manage* 2006; 52(6):68–70
- Pietrzak WS, Eppley BL. Platelet rich plasma: biology and new technology. *J Craniofac Surg* 2005; 16(6):1043–1054. <https://doi.org/10.1097/01.scs.0000186454.07097.bf>
- Lindeboom JA, Mathura KR, Aartman IH et al. Influence of the application of platelet-enriched plasma in oral mucosal wound healing. *Clin Oral Implants Res* 2007 Feb; 18(1):133–139. <https://doi.org/10.1111/j.1600-0501.2006.01288.x>
- Wrotniak M, Bielecki T, Gaździk TS. Current opinion about using the platelet-rich gel in orthopaedics and trauma surgery. *Ortop Traumatol Rehabil* 2007; 9(3):227–238
- Fréchette JP, Martineau I, Gagnon G. Platelet-rich plasmas: growth factor content and roles in wound healing. *J Dent Res* 2005; 84(5):434–439. <https://doi.org/10.1177/154405910508400507>
- Bhanot S, Alex JC. Current applications of platelet gels in facial plastic surgery. *Facial Plast Surg* 2002; 18(1):027–034. <https://doi.org/10.1055/s-2002-19824>
- Nachman RL, Rafii S. Platelets, petechiae, and preservation of the vascular wall. *N Engl J Med* 2008; 359(12):1261–1270. <https://doi.org/10.1056/NEJMra0800887>
- Rendu F, Brohard-Bohn B. The platelet release reaction: granules' constituents, secretion and functions. *Platelets* 2001; 12(5):261–273. <https://doi.org/10.1080/09537100120068170>
- Anitua E, Andia I, Ardanza B et al. Autologous platelets as a source of proteins for healing and tissue regeneration. *Thromb Haemost* 2004; 91(01):4–15. <https://doi.org/10.1160/TH03-07-0440>
- Qureshi AH, Chaoji V, Maiguel D et al. Proteomic and phospho-proteomic profile of human platelets in basal, resting state: insights into integrin signaling. *PLoS One* 2009; 4(10):e7627. <https://doi.org/10.1371/journal.pone.0007627>
- Sánchez-González DJ, Méndez-Bolaina E, Trejo-Bahena NI. Platelet-rich plasma peptides: key for regeneration. *Int J Pept* 2012; 2012:1–10. <https://doi.org/10.1155/2012/532519>
- Borregaard N, Cowland JB. Granules of the human neutrophilic polymorphonuclear leukocyte. *Blood* 1997; 89(10):3503–3521
- Cole BJ, Seroyer ST, Filardo G et al. Platelet-rich plasma: where are we now and where are we going? *Sports health: a multidisciplinary approach* 2010; 2(3):203–210. <https://doi.org/10.1177/1941738110366385>
- Xian LJ, Chowdhury SR, Bin Saim A, Idrus RB. Concentration-dependent effect of platelet-rich plasma on keratinocyte and fibroblast wound healing. *Cytotherapy* 2015; 17:293–300. <https://doi.org/10.1016/j.jcyt.2014.10.005>
- Dionysiou D, Demiri E, Foroglou P et al. The effectiveness of intralesional injection of platelet-rich plasma in accelerating the healing of chronic ulcers:

an experimental and clinical study. *Int Wound J* 2013; 10(4):397–406. <https://doi.org/10.1111/j.1742-481X.2012.00996.x>

- Sakata J, Sasaki S, Handa K et al. A retrospective, longitudinal study to evaluate healing lower extremity wounds in patients with diabetes mellitus and ischemia using standard protocols of care and platelet-rich plasma gel in a Japanese wound care program. *Ostomy Wound Manage* 2012; 58(4):36–49
- Kaya F, Kismet K, Ozer H et al. Can platelet-rich plasma be used safely in intra-abdominal operations? *Bratisl Med J* 2016; 117(09):525–529. https://doi.org/10.4149/BLL_2016_102
- Etulain J. Platelets in wound healing and regenerative medicine. *Platelets* 2018; 29(6):556–568. <https://doi.org/10.1080/09537104.2018.1430357>
- Shengyun H, Zuolin W. Platelet-rich plasma-derived growth factors promotes osteogenic differentiation of rat muscle satellite cells: in vitro and in vivo studies. *Cell Biol Int* 2012; 36(12). <http://dx.doi.org/10.1042/CBI20110491>
- Abate M, Di Gregorio P, Schiavone C, Salini V, Tosi U, Muttini A. Platelet rich plasma in tendinopathies: how to explain the failure. *Int J Immunopathol Pharmacol* 2012 Apr; 25(2):325–334. <https://doi.org/10.1177/03946320120250202>
- Casati MZ, de Vasconcelos Gurgel BC, Gonçalves PF et al. Platelet-rich plasma does not improve bone regeneration around peri-implant bone defects—a pilot study in dogs. *Int J Oral Maxillofac Surg* 2007; 36(2):132–136. <https://doi.org/10.1016/j.ijom.2006.06.004>
- Wiechula R. The use of moist wound-healing dressings in the management of split-thickness skin graft donor sites: a systematic review. *Int J Nurs Pract* 2003; 9(2): S9–17
- Bloemen MC, Boekema BK, Vlieg M et al. Digital image analysis versus clinical assessment of wound epithelialization: a validation study. *Burns* 2012; 38(4):501–505. <https://doi.org/10.1016/j.burns.2012.02.003>
- Bloemen MC, van Zuijlen PP, Middelkoop E. Reliability of subjective wound assessment. *Burns* 2011; 37(4):566–571. <https://doi.org/10.1016/j.burns.2011.02.004>
- Läuchli S, Hafner J, Ostheeren S et al. Management of split-thickness skin graft donor sites: a randomized controlled trial of calcium alginate versus polyurethane film dressing. *Dermatology* 2013; 227(4):361–366. <https://doi.org/10.1159/000356122>
- Kaiser D, Hafner J, Mayer D et al. Alginate dressing and polyurethane film versus paraffin gauze in the treatment of split-thickness skin graft donor sites: a randomized controlled pilot study. *Adv Skin Wound Care* 2013; 26(2):67–73. <https://doi.org/10.1097/01.ASW.0000426715.57540.8d>
- Rožman P, Bolta Z. Use of platelet growth factors in treating wounds and soft-tissue injuries. *Acta Dermatovenerol Alp Pannonica Adriat* 2007; 16(4):156–165
- Bernuzzi G, Tardito S, Bussolati O et al. Platelet gel in the treatment of cutaneous ulcers: the experience of the Immunohaematology and Transfusion Centre of Parma. *Blood Transfus* 2010; 8(4):237–247
- Aggour RL, Gamil L. Antimicrobial effects of platelet-rich plasma against selected oral and periodontal pathogens. *Pol J Microbiol* 2017; 66(1):31–37. <https://doi.org/10.5604/17331331.1235227>

Reflective questions

- What is platelet-rich plasma (PRP) and what are its effects on wound healing?
- How much blood is needed to yield 2ml of PRP?
- Name two growth factors in released for platelets. What is their relevance to wound healing?