

Platelet-Rich Plasma for the Aesthetic Surgeon

Jordan P. Sand, MD¹ Vishad Nabili, MD¹ Amit Kochhar, MD² Jeffrey Rawnsley, MD¹
Gregory Keller, MD¹

¹Department of Head and Neck Surgery, University of California Los Angeles David Geffen School of Medicine, Los Angeles, California

²Department of Otolaryngology–Head and Neck Surgery, Keck Medicine at USC, Los Angeles, California

Address for correspondence Jordan P. Sand, MD, Department of Head and Neck Surgery, University of California Los Angeles David Geffen School of Medicine, 200 Medical Plaza, Suite 550, Los Angeles, CA 90095 (e-mail: jordan.p.sand@gmail.com).

Facial Plast Surg 2017;33:437–443.

Abstract

Platelet-rich plasma (PRP) is an autogenously harvested blood plasma containing concentrated levels of platelets and growth factors. PRP has been identified as a promising treatment for enhancing wound healing and has been used for decades in multiple medical specialties including cardiac surgery, oral surgery, ophthalmology, and orthopedic surgery. Growing evidence for multiple aesthetic surgery applications has recently been developed, particularly for hair restoration and skin rejuvenation. The goal of this article is to review the current medical literature on PRP and identify promising applications that may be integrated into a modern aesthetic surgery practice. The evidence for the use of PRP technology is rapidly expanding as a powerful therapy for select cosmetic surgery patients.

Keywords

- ▶ platelet-rich plasma
- ▶ hair restoration
- ▶ aesthetic surgery

Platelet-rich plasma (PRP) is an autogenously harvested serum processed to concentrate platelets and growth factors.¹ The combination of these molecules and cells leads to a potent serum, which can promote stem cell regeneration as well as soft tissue and bone healing. The growth factors identified in PRP include a platelet-derived growth factor, transforming growth factor- β , vascular endothelial growth factor, epidermal growth factor, and insulin-like growth factor. Immunosorbent assay studies have demonstrated these growth factors are present in much higher concentrations in PRP than in whole blood specimens.² These growth factor proteins are known to be highly chemotactic and mitogenic to multiple cell types including monocytes, fibroblasts, stem cells, endothelial cells, and keratinocytes. They are also known to promote angiogenesis, induce neocollagenesis production, and increase vascular permeability.³

The PRP is harvested from a patient's peripheral blood by a centrifugation process to help separate out the platelet-rich contents from other cell types. Once processed, the PRP has five to eight times the concentration of platelets relative to whole blood.¹ Given its autologous origin, this material has been demonstrated to be safe and free from blood-borne pathogens transmissible to the patient. PRP has been used for many years and is accepted in multiple medical fields including cardiac surgery, oral surgery, dentistry, ophthalmology, orthopedics,

and facial/plastic surgery. Within the field of plastic surgery, the use of growth factors to improve healing, augment tissue, and promote stem cell growth is of particular interest. Attempted aesthetic uses include soft tissue augmentation, skin rejuvenation, hair restoration, wound and skin graft healing, and fat graft augmentation. Evidence for the use of PRP within these realms is rapidly expanding with some data demonstrating excellent promise and others with conflicting evidence. This review seeks to identify areas of use of PRP within aesthetic surgery (▶ **Table 1**).

Platelet-Rich Plasma Harvest

Platelet-rich plasma has several different preparations and commercially available systems (i.e., Eclipse, Harvest, Arthrex); and as such, a variety of protocols exist (▶ **Fig. 1**). The most traditional protocol involves dual speed centrifugation. In this protocol, 10 to 20 mL of whole blood is first drawn into a vial containing an anticoagulant. The blood is then treated to an initial centrifugation to allow the blood components to separate. Three layers are typically identified within the centrifuged blood: (1) the bottom layer comprised of red blood cells, (2) the center layer containing white blood cells and platelets, (3) and the top layer which is primarily plasma. The plasma and buffy coat can be harvested and then centrifuged again to harvest a

Table 1 Platelet-rich plasma uses in aesthetic surgery

Platelet-rich plasma: What works
Hair restoration
Skin rejuvenation after CO ₂ skin resurfacing
Skin rejuvenation after skin microneedling
Soft tissue augmentation with or without hyaluronic fillers
Platelet-rich plasma: What doesn't work
Application after rhytidectomy
Platelet-rich plasma: What might work
Augmented fat injection
Skin graft donor-site healing

concentrated platelet pellet. The platelet pellet can be resuspended in a lower volume of plasma and then treated with calcium chloride or trauma to activate the platelets. The activation process causes release of the platelet's α granules, which contain the growth factors intended for use.⁴⁻⁶ Once the platelets are activated, they must be used rapidly otherwise they will become clotted within the syringe.⁶ Some commercially available systems include technology to help further extract the white blood cells by using patented gel separators, and ultimately ease PRP harvest. This provides a theoretical advantage as the white blood cells release collagenase and

elastases, which may impact healing and cell migration.⁷ The concentration of platelets vary based on the protocol for harvest but have been reported to be 2 to 8.5-fold over the normal concentration in whole blood. Before activation of the platelets, harvested PRP can be stably maintained in an anticoagulated state for up to 8 hours.¹ While these commercially available systems have Food and Drug Administration approval for their equipment, all of the treatments discussed in this review are off-label uses of this material.

Platelet-rich fibrin matrix (PRFM) is another method of preparation and has been studied in a variety of contexts.⁸ This substance has a lower platelet concentration and a large volume of plasma and proteins. By including the fibrin, a matrix is created which theoretically binds growth factors and cells. This allows the injectate to act as a natural clot and provide a time-release formulation of the growth factors within the tissues.⁸

Methods

A review was performed using electronic databases. Cochrane Database of Systematic Reviews, Cochrane Central Register of Controlled Trials, MEDLINE "In-Process & Other Non-Indexed Citations," and MEDLINE electronic databases were searched using a combination of the following medical subject heading terms: platelet rich plasma, hair restoration, soft tissue augmentation, platelet rich fibrin matrix, androgenetic hair loss, fat graft augmentation, microneedling,




Fig. 1 Equipment used to harvest platelet-rich plasma (PRP). (A) shows a centrifuge used in the harvest of PRP. (B) shows an empty PRP tube with liquid anticoagulant and also a gel separator. (C) shows the PRP tube immediately following blood draw from the patient. (D) shows the PRP tube following centrifugation with the yellow top layer being the utilized PRP and the gel separating the red blood cells from this layer.

laser skin resurfacing, rhytidectomy, facial rhytids, wound healing. Search results were limited to English results. Articles were identified from January 1, 2001 until November 1, 2016. Article titles and abstracts were scanned for potential relevance. Studies involving PRP and hair restoration, soft tissue augmentation, fat graft augmentation, microneedling, laser skin resurfacing, rhytidectomy or skin grafting were then further evaluated for pertinence to the subject and ultimate inclusion in the review.

Platelet-Rich Plasma: What Works

Hair Restoration

Platelet-rich plasma for use in hair restoration has demonstrated great promise in a wide variety of reports

(**Table 2**).^{9–25} The proposed mechanisms include promotion of stem cell differentiation into hair follicles, activation of antiapoptotic pathways prolonging survival of dermal papilla cells, prolonging anagen phase of the hair cycle, and stimulation of proangiogenic pathways increasing the perifollicular vascular plexus.²⁶ Multiple studies have been published in recent years demonstrating the effect of PRP on stimulation of hair growth for both male and female pattern hair loss. As with the preparations of PRP, a variety of protocols have been developed and described for use in hair restoration bringing some varied results. While there have been conflicting outcomes in some of these studies, trends can be identified from the studies. The most noteworthy trends identified is the need for multiple treatments for significant improvement and increasing evidence for use in androgenetic hair loss (**Fig. 2**).²²

Table 2 Platelet-rich plasma hair restoration protocols by study

Author	Patients enrolled	Number of platelet-rich plasma injections	Injection interval	Results
Alves and Grimalt ²¹	25	3	1 mo	Increase in anagen hairs, telogen hairs, hair density, and terminal hair density
	25 men, 0 women			
Betsi et al ¹⁴	42	5	Total 2 mo treatment time	Improvement in hair pull test
	34 men, 8 women			Subjective improvement in hair volume and quality
Cervelli et al ¹¹	10	3	4 wk	Increase in hair count and density
	10 men, 0 women			Increase in epidermal thickness, hair follicle number, and in blood vessels around follicles
Gentile et al ²⁰	23	3	4 wk	Increase in hair count and density
	23 men, 0 women			Increase in epidermal thickness, hair follicle number, and in blood vessels around follicles
Gkini et al ¹²	20	3	3 wk, booster at 6 mo	Increase hair density, quality, and thickness
	18 men, 2 women			
Kang et al ¹⁷	26	2	3 mo	Increase in hair count and thickness
	15 men, 11 women			
Khatu et al ¹⁵	11	4	2 wk	Increase in follicular unit number
	11 men, 0 women			
Mapar et al ²⁴	19	2	1 mo	No significant improvements noted
	19 men, 0 women			
Marwah et al ¹⁹	10	6	1 wk	Improvement in global pictures in 2/10 patients
	10 men, 0 women			
Puig et al ²³	26	1	One treatment only	No significant improvements noted
	0 men, 26 women			
Schiavone et al ¹⁶	64	4 injections of PRP	3 mo	Improvement in 62/64 patients by first evaluator and 64/64 patients by the second evaluator
	42 men, 22 women	4 injections of plasmatic protein solution		
Sclafani ¹⁸	15	3	4 wk	Hair density increased at 2 and 3 mo after initial treatment
	9 men, 6 women			Hair density decreased at 6 months to baseline
Singhal et al ¹³	10	4	2 wk	All patients with improvement in scalp photos
	8 men, 2 women			65% with reduction in hair pull
Takikawa et al ¹⁰	26	5	Treatment at 0, 2, 4, 6, and 9 wk	Increase in mean cross-section of hairs versus placebo
	16 men, 10 women			Increase in epidermal thickness and in blood vessels around follicles

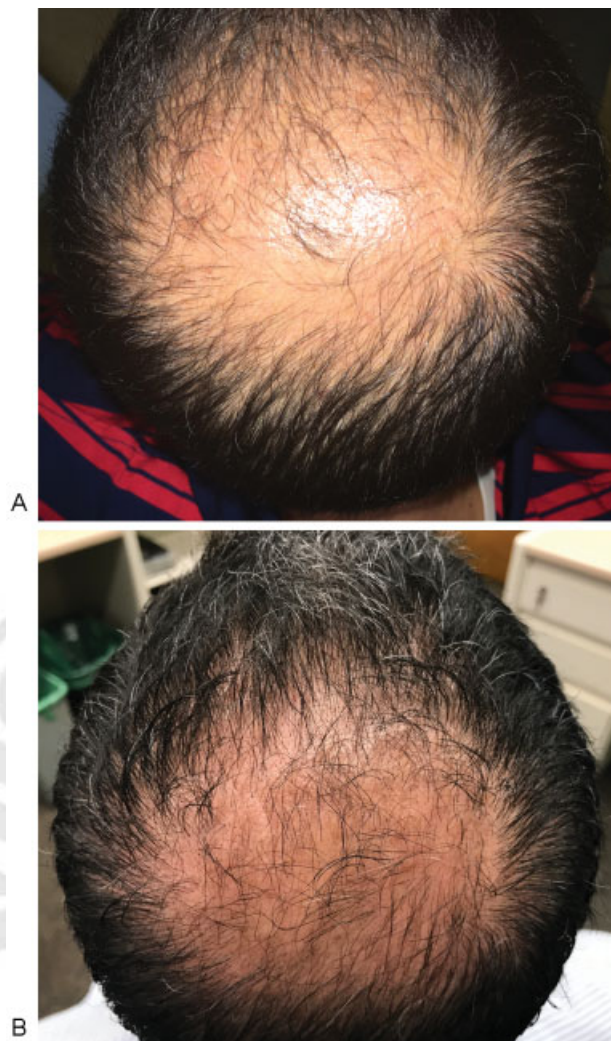


Fig. 2 Male patient from author's practice with androgenetic hair loss treated with three serial monthly injections of platelet-rich plasma. Scalp photos (A) showing preinjection and (B) 1 month after the third injection. Note the increased hair density and thickness.

Androgenetic hair loss has been most closely studied, and several recent studies are summarized below. Recently, Gentile et al randomized 23 patients to receive either PRP injections or saline injections for hair restoration.²⁰ In this protocol, three treatments were provided, each 1 month apart. The patients were followed up for 2 years after the series of injections. At 3 months, a mean increase in total hair density of 45.0 hairs per cm² was measured. No relapse in symptoms was identified until 1 year after treatment. At that time the four patients who demonstrated relapse were retreated. No side effects were noted during the treatment time. In a separate study by Alves and Grimalt, 25 patients with androgenetic alopecia were enrolled in a half-head treatment study for hair restoration.²¹ PRP was injected to one-half of the head and saline was injected into the other half. The protocol involved three injections, each 1 month apart. After 6 months, a statistically significant improvement in anagen hairs, telogen hairs, hair density, and terminal hair density from baseline was identified. There was a significant

increase in hair density compared with the control side as well. In another pilot study from Schiavone et al, 64 patients were treated with PRP for hair restoration with two injections occurring 3 months apart.¹⁶ This study showed a response rate of approximately 50% for clinically important differences by macrophotographs. In another randomized controlled study by Mapar et al, 19 men with androgenetic alopecia were randomized to receive PRP into one scalp site, and saline injected into another.²⁴ Two sessions were completed 1 month apart, and hair was counted at 1, 3, and 6 months after injections. This study did not identify any increase in hair density. Female androgenetic hair loss has also been specifically studied in a double-blind, placebo-controlled manner. In a study by Puig et al, 26 women with female androgenetic alopecia were treated.²³ A total of 15 patients received PRP and 11 were treated with saline. In this study, each patient received only one treatment, and then they were evaluated after 6 months. At the study endpoint, there were no significant improvements in any of the categories evaluated. In a separate meta-analysis evaluating the effect of PRP on androgenetic hair loss, 13 studies were identified where PRP was used for hair restoration.²² Of these, four studies were combined for a total of 60 patients, with hair density as the outcome measure. The study authors concluded that PRP was an effective treatment for androgenetic alopecia. While some of these particular studies are discouraging, they are also problematic as the protocols used are varied. With some exceptions, most successful protocols involve at least three treatments, spaced monthly.

Another hair loss diagnosis that has been evaluated with positive results is alopecia areata. In one recent study by Trink et al, 45 patients with alopecia areata were randomized to receive intralesional injections of PRP, triamcinolone acetonide, or placebo on one-half of the scalp while the other half went untreated.²⁵ The patients treated with PRP were noted to have a significant increase in hair regrowth, decreased hair dystrophy, and decrease in the burning and itching sensations when compared with the triamcinolone acetonide or placebo injections.

Though the evidence for the use of PRP in hair restoration does include some conflicting information, this may be attributed to the types of protocols used. Three monthly serial injections appear to be a minimum number to achieve a clinically important result. Many of the reports utilizing fewer injections did not lead to significant improvements. Larger, higher-powered studies are needed to confirm these pilot results and help our understanding of the differing effects of timing of PRP and hair restoration physiology.

Skin Rejuvenation with Fractionated Resurfacing or Microneedling

Platelet-rich plasma has been strongly implicated in wound healing; and as such, application of PRP following skin rejuvenation procedures has been carefully investigated. After fractional laser resurfacing or microneedling procedures, small holes created in the skin can act as an effective avenue for the topical delivery of PRP. Asif et al evaluated the effect of microneedling with subsequent PRP application on 50 patients

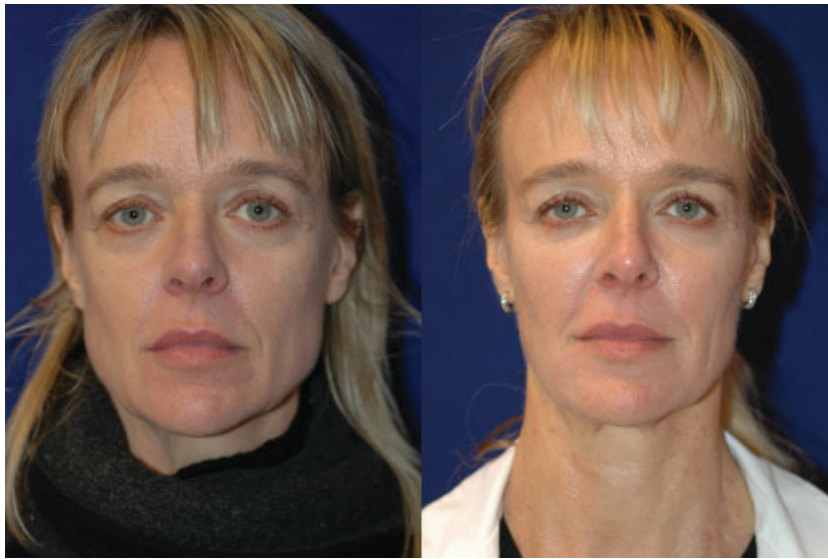

Fig. 3 Female patient who underwent erbium: YAG fractional skin resurfacing followed by topical application of platelet-rich plasma (PRP) and injection of PRP into cheeks and under the eyelids. Posttreatment photos are taken after 20 months. Note the long-lasting changes in skin quality and improvement of tear trough hollowing. (Image provided courtesy of Gregory S. Keller, MD.)

with acne scarring.²⁷ This was done via a split face treatment, with one hemiface receiving distilled water and one hemiface receiving PRP. The authors were able to demonstrate that the PRP-treated side showed a greater reduction in acne scarring by Goodman's quantitative scale. Lee et al evaluated CO₂ laser resurfacing for acne scarring followed by application of PRP versus normal saline. They were able to demonstrate a decrease in erythema, edema, and improved overall appearance on the PRP-treated side.²⁸ Kim and Gallo performed a similar trial to evaluate PRP on forearm wounds created with fractional laser treatment. A total of 15 patients were enrolled and randomized to receive PRP on one arm and saline on the other. There was a significant improvement in erythema, edema, discomfort, and pruritus noted on the PRP-treated arm.²⁹ Another similar study performed by Na et al demonstrated thicker neocollagen growth, as well as less transepidermal water loss, erythema, and inflammatory pigmentation.³⁰ In a separate investigation by Shin et al, patients were treated with PRP following CO₂ fractional resurfacing. The PRP-treated patients had improved satisfaction, skin elasticity, and decreased erythema. Biopsies performed on the patients showed increased fibroblasts and collagen amounts.³¹ These studies, as well as the author's personal experience, provide emerging evidence that PRP improves healing following skin rejuvenation procedures (► Fig. 3).

Platelet-Rich Plasma for Soft Tissue Augmentation with or without Hyaluronic Fillers

The use of PRP for soft tissue augmentation in combination with hyaluronic acid fillers has been utilized for years in aesthetic surgery offices and popularized as the "Vampire Facelift."³² The theory is to combine the soft tissue augmentation agent, such as hyaluronic acid, with PRP to serve as a scaffold for the PRP and ultimately induce a synergistic effect of soft tissue augmentation and skin rejuvenation (► Fig. 4).

In one recent study by Ulusal, 94 patients were treated with PRP and hyaluronic acid mix. There was significant improvement in general skin appearance, texture, and firmness demonstrating these sought after effects.³³

Both PRP and PRFM have also been studied as substrates for soft tissue augmentation without the use of hyaluronic acid fillers. Sclafani and others have demonstrated positive and lasting results of dermal augmentation with PRP or PRFM in nasolabial folds, facial rhytids, and depressed or scarred areas.^{8,34,35} Sclafani has also shown that injections of PRFM induce dermal collagenesis, adipogenesis, and angiogenesis in a histologic study.⁷ In another large study by Kamakura et al, 2,005 patients were treated with PRP plus an fibroblast growth factor (FGF) additive. This mixture was injected into multiple areas of the face including the nasolabial folds, marionette

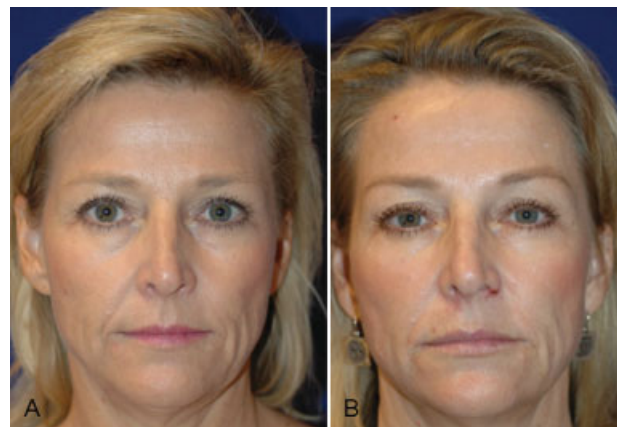

Fig. 4 (A and B) Female patient who underwent hyaluronic acid injection in combination with platelet-rich plasma. Posttreatment photos are taken after 3 weeks. Note the cheek volume improvement, nasolabial fold obliteration, and improvement in the tear trough. (Image provided courtesy of Gregory S. Keller, MD.)

lines, nasojugal grooves, supraorbital grooves, midcheek grooves, foreheads, temples, and glabella with positive effects.³⁶ In a separate study by Redaelli et al, 23 patients were treated with PRP injection into facial rhytids once a month for three consecutive months, and demonstrated a clinical improvement in skin tonicity and facial rhytids.³⁷ These studies have provided strong preliminary evidence of improvement with this technique, but further study is required.

Platelet-Rich Plasma: What Doesn't Work

Platelet-Rich Plasma Application during Rhytidectomy

While the initial use of fibrin glue during rhytidectomy had held promising results for complication reduction, these results are still being evaluated.^{38–40} The use of PRP grew out of this trend in an attempt to help with healing and ecchymosis following cervicofacial rhytidectomy. Farrior and Ladner treated eight women with PRP to the skin flap after standard deep plane rhytidectomy and noted minimal improvements in ecchymosis or edema.⁴¹ In another analysis of 1,089 facelifts by Costa et al, 589 received PRP. When compared with the non-PRP group, there was no difference in hematoma rates between the two groups.⁴² These results have demonstrated a likely equivocal result when utilizing PRP in this setting.

Platelet-Rich Plasma: What Might Work

Platelet-Rich Plasma-Augmented Fat Injection

Autologous fat grafting supplemented with PRP with the intent of enhancing fat survival has demonstrated mixed results. In a study by Salgarello et al, there was no effect identified in a retrospective review of 42 women who underwent breast fat grafting.⁴³ However, in another review of six preclinical studies and nine clinical studies by Serra-Mestre et al, a dose-dependent trend was identified with a measurable positive effect on fat grafts and a low complication rate.⁴⁴ In a separate study of 49 patients with HIV-associated facial fat atrophy, randomized to receive an autologous fat injection with or without PRP, no difference was seen at 12 months by both radiographic and photographic measurements.⁴⁵ However, other investigation has shown a potential positive effect with improved volume retention and subjective patient-reported outcomes with decreased revision rates.⁴⁶ Decreased ecchymosis and maintenance of volume has also been shown with combining PRFM.^{8,47} While this evidence is conflicting; additional study is warranted to help delineate if any effect can be seen.

Platelet-Rich Plasma for Skin Graft Donor Site

Some evidence has been found for the use of PRP as a substrate to help improve wound healing of skin graft donor sites. In one study of five patients with multiple skin graft donor sites, one of the sites was treated with PRP and compared with the control sites. The initial dressing change was performed on postoperative day 7. The investigators were able to demonstrate a significant reduction in donor-site pain, a significant source of morbidity for these patients.⁴⁸ Further study of PRP in this application is warranted.

Conclusion

Platelet-rich plasma is an easily adaptable and promising technology that has demonstrated excellent potential in multiple medical fields, including aesthetic surgery. Hair restoration and skin rejuvenation applications have the highest level of evidence for use based on the currently available medical literature. Evidence for other plastic surgery applications is emerging, and multiple other uses are being evaluated. While pilot data for PRP are being developed, high-powered randomized controlled trials are lacking, and clinical experience primarily directs use. Reported complications of the therapy are few, making this a relatively safe treatment for aesthetic applications. If the evidence for use continues to remain positive, implementation of this technology into plastic surgery practices can be easily and rapidly performed.

References

- 1 Kang RS, Lee MK, Seth R, Keller GS. Platelet-rich plasma in cosmetic surgery. *Int J Otorhinolaryngol Clin* 2013;5(01):24–28
- 2 Babbush CA, Kevy SV, Jacobson MS. An in vitro and in vivo evaluation of autologous platelet concentrate in oral reconstruction. *Implant Dent* 2003;12(01):24–34
- 3 Sclafani AP, Romo T III, Ukrainsky G, et al. Modulation of wound response and soft tissue ingrowth in synthetic and allogeneic implants with platelet concentrate. *Arch Facial Plast Surg* 2005;7(03):163–169
- 4 Bhanot S, Alex JC. Current applications of platelet gels in facial plastic surgery. *Facial Plast Surg* 2002;18(01):27–33
- 5 Eppley BL, Woodell JE, Higgins J. Platelet quantification and growth factor analysis from platelet-rich plasma: implications for wound healing. *Plast Reconstr Surg* 2004;114(06):1502–1508
- 6 Kevy S, Jacobson M. Preparation of growth factors enriched autologous platelet gel. In: *Proceedings of the 27th Annual Meeting of Service Biomaterials*; April, 2001; St. Paul, MN
- 7 Sclafani AP, McCormick SA. Induction of dermal collagenesis, angiogenesis, and adipogenesis in human skin by injection of platelet-rich fibrin matrix. *Arch Facial Plast Surg* 2012;14(02):132–136
- 8 Sclafani AP. Safety, efficacy, and utility of platelet-rich fibrin matrix in facial plastic surgery. *Arch Facial Plast Surg* 2011;13(04):247–251
- 9 Singh B, Goldberg LJ. Autologous platelet-rich plasma for the treatment of pattern hair loss. *Am J Clin Dermatol* 2016;17(04):359–367
- 10 Takikawa M, Nakamura S, Nakamura S, et al. Enhanced effect of platelet-rich plasma containing a new carrier on hair growth. *Dermatol Surg* 2011;37(12):1721–1729
- 11 Cervelli V, Garcovich S, Bielli A, et al. The effect of autologous activated platelet rich plasma (AA-PRP) injection on pattern hair loss: clinical and histomorphometric evaluation. *BioMed Res Int* 2014;2014:760709
- 12 Gkini MA, Kouskoukis AE, Tripsianis G, Rigopoulos D, Kouskoukis K. Study of platelet-rich plasma injections in the treatment of androgenetic alopecia through an one-year period. *J Cutan Aesthet Surg* 2014;7(04):213–219
- 13 Singhal P, Agarwal S, Dhot PS, Sayal SK. Efficacy of platelet-rich plasma in treatment of androgenic alopecia. *Asian J Transfus Sci* 2015;9(02):159–162
- 14 Betsi EE, Germain E, Kalbermatten DF, et al. Platelet-rich plasma injection is effective and safe for the treatment of alopecia. *Eur J Plast Surg* 2013;36:407–412
- 15 Khatu SS, More YE, Gokhale NR, Chavhan DC, Bendsure N. Platelet-rich plasma in androgenic alopecia: myth or an effective tool. *J Cutan Aesthet Surg* 2014;7(02):107–110

- 16 Schiavone G, Raskovic D, Greco J, Abeni D. Platelet-rich plasma for androgenetic alopecia: a pilot study. *Dermatol Surg* 2014;40(09):1010–1019
- 17 Kang JS, Zheng Z, Choi MJ, Lee SH, Kim DY, Cho SB. The effect of CD34+ cell-containing autologous platelet-rich plasma injection on pattern hair loss: a preliminary study. *J Eur Acad Dermatol Venereol* 2014;28(01):72–79
- 18 Sclafani AP. Platelet-rich fibrin matrix (PRFM) for androgenetic alopecia. *Facial Plast Surg* 2014;30(02):219–224
- 19 Marwah M, Godse K, Patil S, Nadkarni N. Is there sufficient research data to use platelet-rich plasma in dermatology? *Int J Trichology* 2014;6(01):35–36
- 20 Gentile P, Garcovich S, Bielli A, Sciola MG, Orlandi A, Cervelli V. The effect of platelet-rich plasma in hair regrowth: a randomized placebo-controlled trial. *Stem Cells Transl Med* 2015;4(11):1317–1323
- 21 Alves R, Grimalt R. Randomized placebo-controlled, double-blind, half-head study to assess the efficacy of platelet-rich plasma on the treatment of androgenetic alopecia. *Dermatol Surg* 2016;42(04):491–497
- 22 Gupta AK, Carviel JL. Randomized placebo-controlled, double-blind, meta-analysis of efficacy of platelet-rich plasma therapy for androgenetic alopecia. *J Dermatolog Treat* 2016;9:1–4
- 23 Puig CJ, Reese R, Peters M. Double-blind, placebo-controlled pilot study on the use of platelet-rich plasma in women with female androgenetic alopecia. *Dermatol Surg* 2016;42(11):1243–1247
- 24 Mapar MA, Shahriari S, Haghighizadeh MH. Efficacy of platelet-rich plasma in the treatment of androgenetic (male-patterned) alopecia: A pilot randomized controlled trial. *J Cosmet Laser Ther* 2016;18(08):452–455
- 25 Trink A, Sorbellini E, Bezzola P, et al. A randomized, double-blind, placebo- and active-controlled, half-head study to evaluate the effects of platelet-rich plasma on alopecia areata. *Br J Dermatol* 2013;169(03):690–694
- 26 Gupta AK, Carviel J. A mechanistic model of platelet-rich plasma treatment for androgenetic alopecia. *Dermatol Surg* 2016;42(12):1335–1339
- 27 Asif M, Kanodia S, Singh K. Combined autologous platelet-rich plasma with microneedling versus microneedling with distilled water in the treatment of atrophic acne scars: a concurrent split-face study. *J Cosmet Dermatol* 2016;15(04):434–443
- 28 Lee JW, Kim BJ, Kim MN, Mun SK. The efficacy of autologous platelet rich plasma combined with ablative carbon dioxide fractional resurfacing for acne scars: a simultaneous split-face trial. *Dermatol Surg* 2011;37(07):931–938
- 29 Kim H, Gallo J. Evaluation of the effect of platelet-rich plasma on recovery after ablative fractional photothermolysis. *JAMA Facial Plast Surg* 2015;17(02):97–102
- 30 Na JI, Choi JW, Choi HR, et al. Rapid healing and reduced erythema after ablative fractional carbon dioxide laser resurfacing combined with the application of autologous platelet-rich plasma. *Dermatol Surg* 2011;37(04):463–468
- 31 Shin MK, Lee JH, Lee SJ, Kim NI. Platelet-rich plasma combined with fractional laser therapy for skin rejuvenation. *Dermatol Surg* 2012;38(04):623–630
- 32 Runels C. *Vampire Facelift: The Secret Blood Method to Revive Youth & Restore Beauty*. Fairhope, AL: CreateSpace Independent Publishing Platform; 2013
- 33 Ulusal BG. Platelet-rich plasma and hyaluronic acid - an efficient biostimulation method for face rejuvenation. *J Cosmet Dermatol* 2017;16(01):112–119
- 34 Sclafani AP, Azzi J. Platelet preparations for use in facial rejuvenation and wound healing: a critical review of current literature. *Aesthetic Plast Surg* 2015;39(04):495–505
- 35 Elnehrawy NY, Ibrahim ZA, Eltoukhy AM, Nagy HM. Assessment of the efficacy and safety of single platelet-rich plasma injection on different types and grades of facial wrinkles. *J Cosmet Dermatol* 2017;16(01):103–111
- 36 Kamakura T, Kataoka J, Maeda K, et al. Platelet-rich plasma with basic fibroblast growth factor for treatment of wrinkles and depressed areas of the skin. *Plast Reconstr Surg* 2015;136(05):931–939
- 37 Redaelli A, Romano D, Marciánó A. Face and neck revitalization with platelet-rich plasma (PRP): clinical outcome in a series of 23 consecutively treated patients. *J Drugs Dermatol* 2010;9(05):466–472
- 38 Marchac D, Sándor G. Face lifts and sprayed fibrin glue: an outcome analysis of 200 patients. *Br J Plast Surg* 1994;47(05):306–309
- 39 Marchac D, Greensmith AL. Early postoperative efficacy of fibrin glue in face lifts: a prospective randomized trial. *Plast Reconstr Surg* 2005;115(03):911–916, discussion 917–918
- 40 Jones BM, Grover R. Avoiding hematoma in cervicofacial rhytidectomy: a personal 8-year quest. Reviewing 910 patients. *Plast Reconstr Surg* 2004;113(01):381–387, discussion 388–390
- 41 Farrior E, Ladner K. Platelet gels and hemostasis in facial plastic surgery. *Facial Plast Surg* 2011;27(04):308–314
- 42 Costa CR, Ramanadham SR, O'Reilly E, Coleman JE, Rohrich RJ. The role of the superwet technique in face lift: an analysis of 1089 patients over 23 years. *Plast Reconstr Surg* 2015;135(06):1566–1572
- 43 Salgarello M, Visconti G, Rusciani A. Breast fat grafting with platelet-rich plasma: a comparative clinical study and current state of the art. *Plast Reconstr Surg* 2011;127(06):2176–2185
- 44 Serra-Mestre JM, Serra-Renom JM, Martínez L, Almadori A, D'Andrea F. Platelet-rich plasma mixed-fat grafting: a reasonable pro-survival strategy for fat grafts? *Aesthetic Plast Surg* 2014;38(05):1041–1049
- 45 Fontdevila J, Guisantes E, Martínez E, Prades E, Berenguer J. Double-blind clinical trial to compare autologous fat grafts versus autologous fat grafts with PDGF: no effect of PDGF. *Plast Reconstr Surg* 2014;134(02):219e–230e
- 46 Cervelli V, Gentile P, Sciola MG, et al. Application of platelet-rich plasma in plastic surgery: clinical and in vitro evaluation. *Tissue Eng Part C Methods* 2009;15(04):625–634
- 47 Azzena B, Mazzoleni F, Abatangelo G, Zavan B, Vindigni V. Autologous platelet-rich plasma as an adipocyte in vivo delivery system: case report. *Aesthetic Plast Surg* 2008;32(01):155–158, discussion 159–161
- 48 Miller JD, Rankin TM, Hua NT, et al. Reduction of pain via platelet-rich plasma in split-thickness skin graft donor sites: a series of matched pairs. *Diabet Foot Ankle* 2015;6:24972