



ELSEVIER

ORIGINAL ARTICLE

First clinical experience with a new injectable recombinant human collagen scaffold combined with autologous platelet-rich plasma for the treatment of lateral epicondylar tendinopathy (tennis elbow)

Uri Farkash, MD^{a,*}, Erez Avisar, MD^b, Ido Volk, MD^c, Omer Slevin, MD^d,
 Noam Shohat, MD^b, Madi El Haj, MD^c, Eran Dolev, MD^d, Eran Ashraf, MD^b,
 Shai Luria, MD^c

^aDepartment of Orthopedic Surgery, Assuta-Ashdod University Hospital, Ashdod, Israel, and Faculty of Health Sciences, Ben Gurion University of the Negev, Beer Sheva, Israel

^bDepartment of Orthopedic Surgery, Assaf Haroffeh Medical Center, Zrifin, Israel

^cDepartment of Orthopedic Surgery, Hadassah-Hebrew University Medical Center, Jerusalem, Israel

^dDepartment of Orthopedic Surgery, Meir Hospital, Kfar-Saba, Israel

Background: Lateral epicondylitis is a tendinopathy of the common extensor origin at the elbow. When traditional conservative treatment fails, more effective therapies are needed. Vergenix Soft Tissue Repair (STR) Matrix (CollPlant Ltd., Ness-Ziona, Israel) is an injectable gel composed of cross-linked bioengineered recombinant human type I collagen combined with autologous platelet-rich plasma (STR/PRP). The complex forms a collagen-fibrin matrix that promotes cell migration and tissue repair. Based on positive outcomes from preclinical trials, this study is the first clinical trial of STR/PRP on tendinopathy. We hypothesized that STR/PRP would be a safe and effective treatment for lateral epicondylar tendinopathy.

Methods: Patients with chronic lateral epicondylitis underwent treatment with STR/PRP. Outcome assessment included grip strength, functional disability, and changes in sonographic tendon appearance for up to 6 months after treatment.

Results: The study enrolled 40 patients. No systemic or local severe adverse events were reported. Clinical evaluation revealed an improvement in the mean Patient-Rated Tennis Elbow Evaluation score from 64.8 before treatment and showed a 59% reduction at 6 months. The 12-Item Short-Form Health Survey questionnaire showed improvement from a mean score of 30.7 to 37.7 at the final follow-up. Grip strength increased from 28.8 kg at baseline to 36.8 kg at 6 months. Improvements in sonographic tendon appearance were evident among 68% of patients.

The Israeli Ministry of Health Clinical Trial Department approved this single-arm open-label multicenter study (HTA6961).

This single-arm open-label multicenter study was registered on clinicaltrials.gov (NCT02309307) before patient enrollment.

*Reprint requests: Uri Farkash, MD, 7 Ha'refua Str. Assuta Hospital, Ashdod 7747629, Israel.

E-mail address: urifarkash@gmail.com (U. Farkash).

Conclusion: STR/PRP is a safe treatment that effectively induces clinically significant improvements in elbow symptoms and general well-being as well as objective measures of strength and imaging of the common extensor tendon within 6 months of treatment of elbow tendinopathy recalcitrant to standard treatments.

Level of evidence: Level IV; Case Series; Treatment study

© 2018 Journal of Shoulder and Elbow Surgery Board of Trustees. All rights reserved.

Keywords: Elbow; tendinopathy; lateral epicondylitis; tennis elbow; recombinant human type I collagen; rhCOL1

Chronic, painful tendon complaints are frequent in athletic and also in inactive individuals¹⁸ and are commonly presented to general and sports medicine consultants.⁴ They might lead to alterations in normal daily activity levels and sometimes to discontinuance of sporting activities.¹⁸ Repetitive strain and overuse injury of the common extensor origin at the elbow may result in chronic lateral epicondylar tendinopathy,^{6,38} which is frequently named “tennis elbow.” This condition has a prevalence of 1% to 3%, peaks between ages 45 and 54, is equally common in men and women,^{19,33,40} and is characterized by degenerative changes and microtearing of the common extensor origin, mainly the extensor carpi radialis brevis, at its attachment to the lateral epicondyle.^{22,24} Sonographic examinations suggest a degenerative pathologic origin,² but the role of inflammation is still debated.^{8,37}

The diagnosis relies mainly on the clinical examination, which includes tenderness over the common extensor origin and a painful resistance against dorsiflexion of the wrist.⁶ Some cases of chronic lateral epicondylitis (LE) can be resistant to traditional conservative treatment options, and to avoid surgery, more effective conservative therapies are needed.

There is evolving evidence that platelet-rich plasma (PRP) can promote tissue regeneration, although the mechanism by which autologous blood products (ABPs) enhance healing processes has not yet been determined. Growth factors released by platelets, in association with other cytokines or cellular and humoral mediators contained in ABPs, have been demonstrated to expedite repair mechanisms, including enhancement of tenocyte proliferation and overall tendon healing. Moreover, several bioactive proteins within ABPs attract osteoblasts and macrophages, which remove the necrotic tissue.^{20,31,36} Therefore, PRP injection to treat LE has gained popularity.^{1,5} A recent review concluded that the evidence suggests a modest effect of PRP in treatment of refractory cases of lateral elbow tendinopathy.¹⁰

Collagens boast a long history of medical and industrial use in healing procedures and tissue reconstruction, where their abundance, biocompatibility, biodegradability, and functionality makes them ideal scaffolding materials for human use. Collagen-based scaffolds provide beneficial features in defining the space for tissue ingrowth and in serving as tissue equivalents. These scaffolds can be customized to attract specific cell types or saturated with factors to be released at the graft site. Collagen scaffolds designed to closely resemble the natural extracellular matrix (ECM) environment form the basis of cell therapies aimed at accelerating restoration of

diseased tissues.^{12,21} Throughout the multistage wound healing process, collagen and collagen-derived fragments provide imperative support for cell aggregation and adhesion, clot formation, fibroblast recruitment, and adequate scar tissue generation.¹³ Biocompatible collagen-based wound dressings contribute local hemostatic and chemotactic stimuli while supplying a structural support upon which neotissue can be formed at enhanced rates.

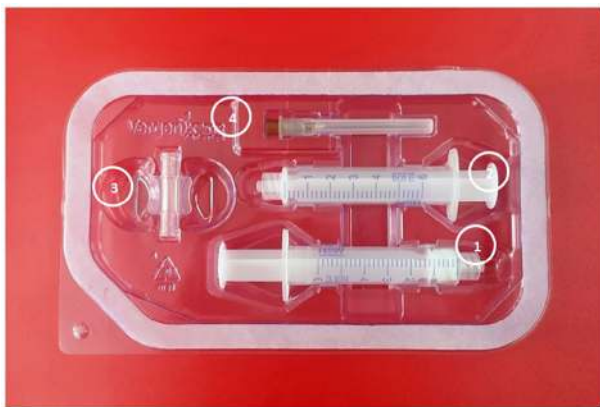Vergenix Soft Tissue Repair (STR) Matrix (CollPlant Ltd., Ness-Ziona, Israel) is an injectable gel composed of cross-linked bioengineered recombinant human type I collagen (rhCOL1) combined with autologous PRP (STR/PRP). Upon injection into an injury site, the complex forms a collagen-fibrin matrix. The collagen serves as a natural scaffold for the adhesion and proliferation of the cells involved in tendon healing. Once the cells attach and proliferate, they secrete the natural ECM. Fibroblasts proliferate and become aligned on the collagen scaffold, resulting in faster maturation. The collagen scaffold retains the platelets-related growth factors, such as platelet-derived growth factor and vascular endothelial growth factor in the vicinity of the injury site, thus enhancing the effect of these growth factors.^{9,39}

In the current study, we evaluated the safety and efficacy of STR/PRP in the treatment of LE. We hypothesized that STR, through its ability to promote cell migration and tissue repair,¹² would result in a relief of clinical symptoms and evidence of tendon regeneration and healing.

Materials and methods

Adult patients presenting chronic LE, manifesting by lateral elbow pain for at least 3 months and pain elicited with active extension of the wrist in pronation and elbow extension, were eligible to participate in the study. Previous therapy, including physical therapy exercises (stretches and eccentric loading) and nonsteroidal anti-inflammatory (NSAID) medications, had failed in all patients included in the trial. Patients who previously received local injections, including steroids, were only eligible to participate if at least 30 days passed since the last injection. Excluded were patients with rheumatoid arthritis, inflammatory disease, or fibromyalgia, and patients receiving anticoagulant medications, with skin bruise around the elbow, or who previously underwent surgery for LE.

Patient enrollment included a detailed trial description, and the patients signed a consent form. A physical examination, including a grip strength test, was performed with the patients seated with their elbows flexed, wrists and forearms in a neutral position, using a Jamar



Vergenix™STR Soft Tissue Repair Device is a single use Tyvek blister kit that contains:

- (1) Syringe with lyophilized Type I rhCollagen
- (2) Empty syringe
- (3) Luerlock connector
- (4) 19G needle

Figure 1 Vergenix Soft Tissue Repair (STR) kit (CollPlant Ltd., Ness-Ziona, Israel).

dynamometer (Baseline Hydraulic Hand Dynamometers; Fabrication Enterprises, White Plains, NY, USA). Patients then completed the Patient-Rated Tennis Elbow Evaluation (PRTEE)¹⁷ and 12-Item Short-Form Health Survey (SF-12)⁴¹ questionnaires.

Laboratory tests, including a complete blood count and chemistry, and an ultrasonographic evaluation of both elbows were performed within 2 weeks before initiating treatment. The ultrasound examinations were performed by a dedicated physician experienced in musculoskeletal sonography. Common extensor tendon thickness, sonographic appearance, and Doppler activity were assessed, using a method previously described by Krogh et al.¹⁵

Before preparation of the STR/PRP mix, lidocaine (1 mL) was injected into the subcutaneous lateral aspect of the elbow with a 25-gauge needle. Blood was collected, and a commercial mononuclear-rich PRP kit (Tropocells Plus; Estar Medical, Holon, Israel) was used to separate the plasma component and isolate the PRP.

The Vergenix STR single-use, sterile kit contains a syringe with lyophilized rhCollagen and calcium chloride, an empty syringe, a Luer lock connector, and a 19-gauge needle (Fig. 1). The PRP is mixed with Vergenix STR by withdrawing 2.7 mL PRP to the empty 5 mL syringe, connecting it to the syringe containing the dry collagen, and mixing the material between the 2 syringes until a uniform 3 mL suspension is obtained (Fig. 2). The suspension was injected into the point of maximal tenderness of the extensor tendon in a sterile manner using a 19-gauge needle (Fig. 3).

After treatment, patients were asked not to use or minimally use the arm for 3 to 4 days and thereafter to gradually return to normal activities if the pain level was acceptable. If analgesic drugs were needed, acetaminophen was recommended.

Patients were assessed at 1, 2, 3, and 6 months after undergoing treatment. At each visit, adverse events were recorded, a physical examination, including a grip strength test, was performed, and patients completed the PRTEE and SF-12 questionnaires. Ultrasonography was performed at the 3-month and 6-month visits to measure changes in tendon thickness and Doppler activity. A

reduction in tendon thickness, a reduction in color Doppler activity, or a reduction in the number of hypoechoic centers within the tendon were considered improvements in tendon sonographic appearance. Safety blood chemistry and hematology tests were performed at the 6-month visit.

Statistical analysis of the results was performed using SAS 9.3 software (SAS Institute, Inc., Cary, NC, USA). Continuous variables are presented as means and standard deviation of the means and categorical variables as absolute and relative frequencies. The paired *t* test or signed rank test (whichever was appropriate) was used for comparisons of continuous variables, and the χ^2 test or Fisher exact test (whichever was appropriate) was used for categorical variables. The level of statistical significance was set at $P < .05$ for all analyses.

Results

The study enrolled 40 patients (29 men and 11 women) clinically diagnosed with LE, of whom 12 failed to respond to previous steroid injection treatments. Thirty-nine patients completed the 3-month follow-up visits as scheduled, and 36 participated in the visit conducted 6 months after treatment. Four patients did not complete the follow-up protocol; none of these 4 patients underwent surgery for LE during the follow-up period.

The mean baseline PRTEE score was 64.8, and showed a 34% reduction within 1 month of Vergenix STR treatment ($P < .001$). The score further improved thereafter, peaking at the 6-month follow-up visit, when a mean 59% reduction from baseline was reported ($P < .001$; Table I). At 3 months after treatment, 29 patients (74%) showed a $\geq 25\%$ (or at least 11 points) reduction in the PRTEE score, and at 6 months, 31 of 36 patients (86%) reported a $\geq 25\%$ (or at least 11 points) reduction in the PRTEE score.

Patient-rated functional health and well-being, as measured by the SF-12 questionnaire, also showed continuous improvements throughout the follow-up period, increasing from a mean score of 30.7 before treatment to a mean score of 37.7 at the final follow-up session ($P < .001$; Table I). A continuous improvement in grip strength was also evident after treatment, rising from a mean baseline strength of 29 kg to a mean strength of 37 kg at 6 months ($P < .001$; Table I).

Pretreatment ultrasound examinations showed pathologic findings compatible with LE in 33 of 39 patients. Of these 33 patients, improvements in tendon appearance were evident among 17 patients (52%) 3 months after treatment and in 21 of the 31 patients assessed (68%) at 6 months (Fig. 4). There were no serious adverse events and no reports of infection after the therapy, and no clinically significant abnormalities in laboratory test results were noted during 6 months after treatment. The most common adverse event, reported by 20 patients, was pain or swelling at the injection site that occurred after the injection. Thirteen patients needed oral pain medications (analgesics or NSAIDs) to control the pain, which typically resolved within a few days of treatment.

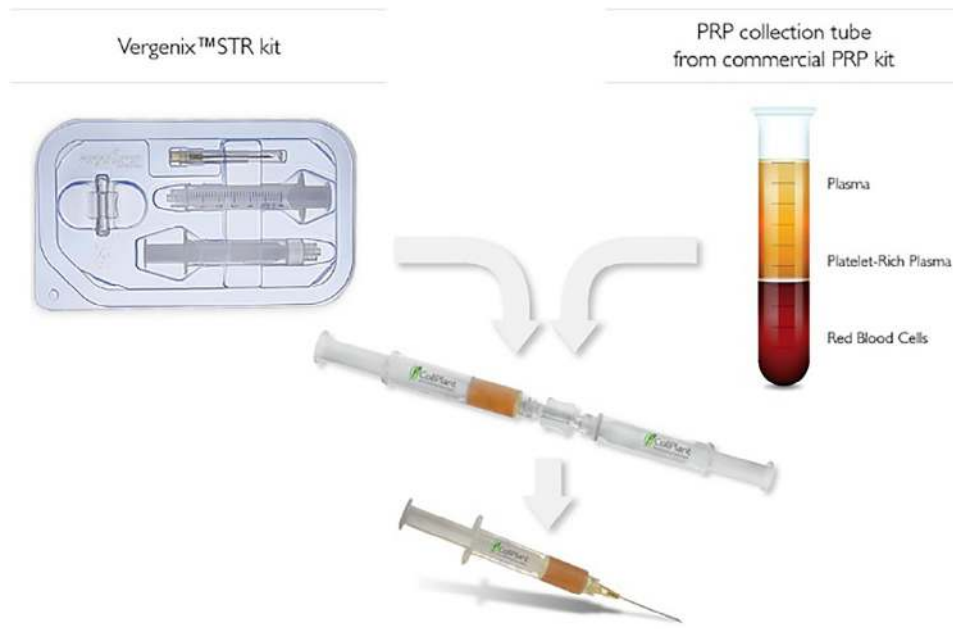


Figure 2 Preparation of Vergenix Soft Tissue Repair (STR) (CollPlant Ltd., Ness-Ziona, Israel) and platelet-rich plasma (PRP) before injection.

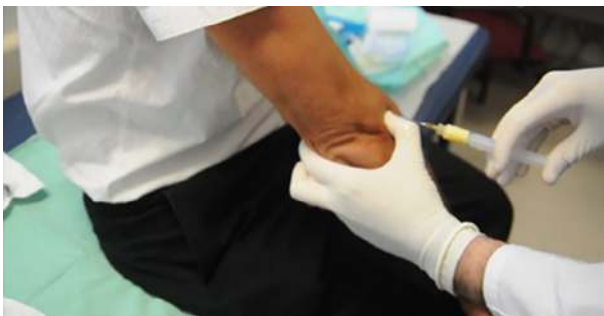

Figure 3 Injection of the Soft Tissue Repair (STR)/platelet-rich plasma (PRP) suspension to the injured common extensor tendon origin.

Discussion

Collagen is a natural scaffold supporting the adhesion and proliferation of the cells involved in tendon healing. Traditionally, commercial collagen is derived from human cadaveric sources or from animal sources. However, there have been concerns regarding the quality and safety of collagen extracted from animal tissue; in particular, its immunogenicity, risk of disease transmission, and overall quality.^{27,29}

The expanding need for safe collagen-based therapeutics led to the development of rhCOL1, derived from genetically engineered tobacco plants.^{34,35} This protein is identical to human type I collagen and showed superior mechanical and biological properties *in vitro* when compared with animal-derived collagen. An rhCollagen-based gel was superior to a commercial bovine-based product and human cadaveric

collagen in promoting wound healing in rat and porcine full-thickness cutaneous wound models.³²

Vergenix STR is an advanced soft tissue repair product composed of a biodegradable rhCollagen-calcium chloride-based scaffold that forms a gel when combined with autologous PRP. Application of the gel to the tendon injury site and the formation of a clot results in the release of growth factors from the activated platelets in the vicinity of the injury site and the attenuation of the inflammatory signals due to the action of platelet-secreted cytokines and growth factors.¹¹ Once the fibroblast cells attach and proliferate, they secrete the natural ECM. Fibroblasts proliferate and align on the rhCollagen scaffold, resulting in faster tissue maturation. The implanted rhCollagen is naturally degraded and eventually replaced by the natural ECM of the cells that initiate the regeneration of the damaged tissue.

When conservative treatment of LE, including NSAID drugs, bracing, and physical therapies fails, local injection therapies of glucocorticoids or PRP, are suggested.⁵ Peerbooms et al²⁸ showed that 50% of LE patients treated with corticosteroid injection and that 73% of those treated with PRP experienced a $\geq 25\%$ reduction in visual analog pain scores or Disability of Arm, Shoulder and Hand scores within 1 year. Creaney et al³ reported clinically significant (≥ 25 -point) improvements on the PRTEE scale 6 months after treatment among 66% of patients treated with PRP.

Vergenix STR performance compares favorably with the published outcomes of standard LE treatments provided to patients resistant to first-line physical therapy. Poltawski et al³⁰ provided estimates of the changes in PRTEE scores that are required to determine whether significant changes have occurred in the clinical symptoms of LE patients and showed

Table I Mean PRTEE and SF-12 scores and grip strength before and after treatment with Soft Tissue Repair/platelet-rich plasma

Variable	No.	PRTEE score				SF-12 score				Grip strength (kg)			
		Mean	SD	Range	<i>P</i> value	Mean	SD	Range	<i>P</i> value	Mean	SD	Range	<i>P</i> value
Before treatment	40	64.8	13.4	50-96	N/A	30.7	5.2	22-42	N/A	29	14.1	5-65	N/A
After treatment													
1 mo	40	43.3	18.9	11.5-77	<.001	33.2	6.4	21-45	.0819	32	14.2	8-69	.0034
2 mo	40	36.9	22.1	0-85.5	<.001	34.9	6.0	18-45	<.001	34	13.4	5-68	<.001
3 mo	39	29.8	21.6	0-84	<.001	35.9	5.5	26-45	<.001	35	11.9	8-70	<.001
6 mo	36	25.6	20.1	0-66	<.001	37.7	4.9	29-47	<.001	37	12.5	8-70	<.001

PRTEE, Patient-Rated Tennis Elbow Evaluation; SF-12, 12-Item Short-Form Health Survey; SD, standard deviation; N/A, not applicable.

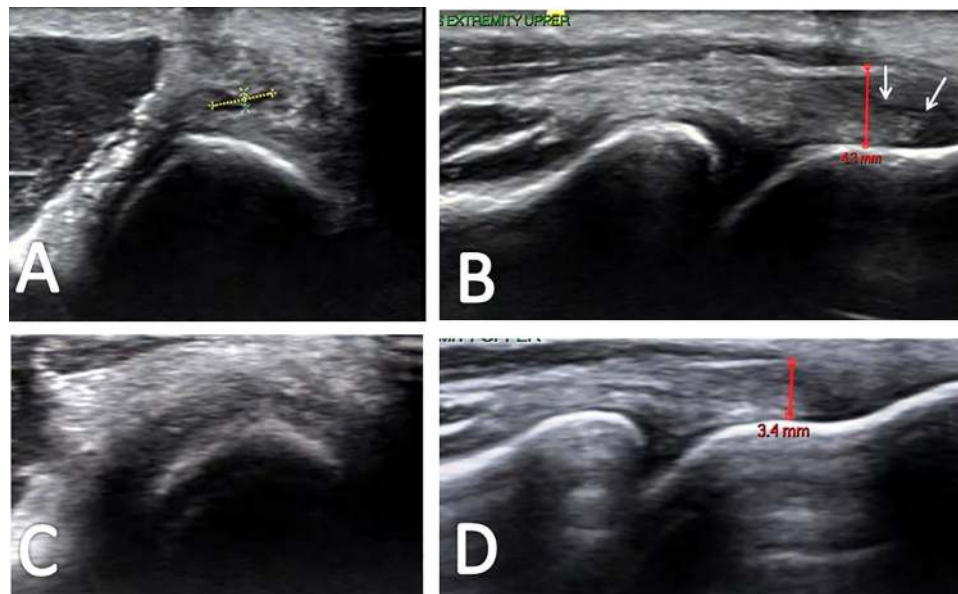


Figure 4 Ultrasonogram in (A) transverse and (B) longitudinal views illustrates the common extensor origin with a partial-thickness tear (dotted line in A and between white arrows in B) before treatment and hypoechoic thickening (up to 4.3 mm). Ultrasonogram in (C) transverse and (D) longitudinal views of the same patient after treatment demonstrates regression of tendinopathic changes, reduction in tendon thickness to 3.4 mm, and resolution of the tear.

that an 11-point reduction in PRTEE scores is considered a substantial improvement. Our results show that 86% of the Verigen STR-treated patients reported a ≥ 11 -point (or at least 25%) reduction in PRTEE scores 6 months after treatment. Enhanced grip strength, which increased by a mean 26% during the study period, corroborates with the subjective patient ratings.

Although named LE, the condition should be termed tendinosis, because histopathologic studies have demonstrated that it involves a fibroblastic and vascular response, called angiofibroblastic degeneration, and not just an inflammatory response.^{23,25} A positive, histologically detectable healing effect of rhCollagen has been shown in various animal models.³² Demonstration of a similar effect in clinical applications is merely impossible.

Our study relied on the sonographic appearance of the common extensor tendon as an indication of a cellular healing process in the tendon because of its noninvasive, cost-effective, quick, and accessible properties compared with magnetic resonance imaging or arthroscopy.¹⁶ The diagnostic

accuracy of ultrasound in detecting LE is diverse, however, with sensitivity ranging from 64% to 100% and specificity exhibiting a wider range of 36% to 100%.¹⁶ This may explain why 6 of our patients who had clinical symptoms of LE did not present abnormal sonographic findings. Nevertheless, an improvement in the appearance of the tendon at 6 months after treatment was noted in 68% of patients who had abnormal baseline sonographic findings.

No serious adverse events occurred in this study, and no patients ceased participation due to adverse events. Much like other injectable treatments for LE,^{7,14,26} transient postinjection pain was the most frequently reported adverse effect of Verigen STR treatment. Ozturan et al²⁶ reported that most patients experienced temporary postinjection pain, which subsided within 2 days. Dojode et al⁷ also reported a 60% rate of postinjection pain at the injection site in patients treated with an ABPs. Some patients experienced persistent pain for several days.

The current study is the first clinical trial of STR/PRP as a treatment for severe, chronic, resistant LE. Although this

pilot clinical study showed encouraging clinical outcomes, with functional improvement and structural repair of the tendon as evidenced by ultrasound, the small number of patients and absence of a control group were limitations of the study. Wolf et al⁴² designed a randomized controlled study with 3 groups of patients—ABP injection, corticosteroid/lidocaine injection, and saline/lidocaine injection—in an attempt to account for a placebo effect associated with the injection. Outcomes improved over time in all 3 groups at the 2-month and 6-month follow-up assessments. The lack of a placebo or other treatment groups in our trial does not allow ruling out a placebo effect or differentiating between the effects of PRP alone and rhCollagen combined with PRP. A follow-up study could compare this new therapy with well-established and common treatment modalities such as a corticosteroid or PRP injections.

The relatively short follow-up period in this study limits predictions of a long-lasting effect of the treatment. However, other studies assessing injection treatments for LE also reported only short-term pain relief. Furthermore, the short-term benefits, or possibly the accelerating effect, of injectable treatments in terms of disability, lost productivity, and quality of life cannot be ruled out.

Conclusion

This study demonstrated that STR/PRP is a new treatment that promotes tissue repair. Our study suggests that STR/PRP effectively induces clinically significant improvements in PRTEE and SF-12 scores as well as in grip strength and in the sonographic appearance of the common extensor tendon within 6 months of treatment of elbow tendinopathy recalcitrant to standard treatments. STR/PRP injection therapy was successful in 86% of the patients who failed to respond to conservative therapy. Double-blind, randomized controlled trials are indicated to determine the efficacy of this new treatment compared with other currently available injection treatments in chronic LE.

Disclaimer

While CollPlant Ltd funded the clinical study, the study was independently designed and conducted in the medical centers; data interpretation and manuscript redaction were also independently undertaken by the authors.

The authors, their immediate families, and any research foundation with which they are affiliated have not received any financial payments or other benefits from any commercial entity related to the subject of this article.

References

- Ahmad Z, Brooks R, Kang SN, Weaver H, Nunney I, Tytherleigh-Strong G, et al. The effect of platelet-rich plasma on clinical outcomes in lateral epicondylitis. *Arthroscopy* 2013;29:1851-62. <https://dx.doi.org/10.1016/j.arthro.2013.07.272>
- Connell D, Burke F, Coombes P, McNealy S, Freeman D, Pryde D, et al. Sonographic examination of lateral epicondylitis. *AJR Am J Roentgenol* 2001;176:777-82.
- Creaney L, Wallace A, Curtis M, Connell D. Growth factor-based therapies provide additional benefit beyond physical therapy in resistant elbow tendinopathy: a prospective, single-blind, randomised trial of autologous blood injections versus platelet-rich plasma injections. *Br J Sports Med* 2011;45:966-71. <https://dx.doi.org/10.1136/bjism.2010.082503>
- deJonge S, van den Berg C, de Vos RJ, van der Heide HJ, Weir A, Verhaar JA, et al. Incidence of midportion Achilles tendinopathy in the general population. *Br J Sports Med* 2011;45:1026-8. <https://dx.doi.org/10.1136/bjsports-2011-090342>
- deVos RJ, van Veldhoven PL, Moen MH, Weir A, Tol JL, Maffulli N. Autologous growth factor injections in chronic tendinopathy: a systematic review. *Br Med Bull* 2010;95:63-77. <https://dx.doi.org/10.1093/bmb/ldq006>
- De Smedt T, de Jong A, Van Leemput W, Lieven D, Van Glabbeek F. Lateral epicondylitis in tennis: update on aetiology, biomechanics and treatment. *Br J Sports Med* 2007;41:816-9. <https://dx.doi.org/10.1136/bjism.2007.036723>
- Dojode CM. A randomised control trial to evaluate the efficacy of autologous blood injection versus local corticosteroid injection for treatment of lateral epicondylitis. *Bone Joint Res* 2012;1:192-7. <https://dx.doi.org/10.1302/2046-3758.18.2000095>
- Fredberg U, Stengaard-Pedersen K. Chronic tendinopathy tissue pathology, pain mechanisms, and etiology with a special focus on inflammation. *Scand J Med Sci Sports* 2008;18:3-15. <https://dx.doi.org/10.1111/j.1600-0838.2007.00746.x>
- Fufa D, Shealy B, Jacobson M, Kevy S, Murray MM. Activation of platelet-rich plasma using soluble type I collagen. *J Oral Maxillofac Surg* 2008;66:684-90. <https://doi.org/10.1016/j.joms.2007.06.635>
- Hall MP, Ward JP, Cardone DA. Platelet rich placebo? Evidence for platelet rich plasma in the treatment of tendinopathy and augmentation of tendon repair. *Bull Hosp Jt Dis* 2013;71:54-9.
- Harrison S, Vavken P, Kevy S, Jacobson M, Zurakowski D, Murray MM. Platelet activation by collagen provides sustained release of anabolic cytokines. *Am J Sports Med* 2011;39:729-34. <https://dx.doi.org/10.1177/0363546511401576>
- Inoue T, Toda S, Narisawa Y, Sugihara H. Subcutaneous adipocytes promote the differentiation of squamous cell carcinoma cell line (DJM-1) in collagen gel matrix culture. *J Invest Dermatol* 2001;117:244-50.
- Krieg T. Collagen in the healing wound. *Wounds* 1995;7(Suppl A):5A-12A.
- Krogh TP, Bartels EM, Ellingsen T, Stengaard-Pedersen K, Buchbinder R, Fredberg U, et al. Comparative effectiveness of injection therapies in lateral epicondylitis: a systematic review and network meta-analysis of randomized controlled trials. *Am J Sports Med* 2013;41:1435-46. <https://dx.doi.org/10.1177/0363546512458237>
- Krogh TP, Fredberg U, Stengaard-Pedersen K, Christensen R, Jensen P, Ellingsen T. Treatment of lateral epicondylitis with platelet-rich plasma, glucocorticoid, or saline: a randomized, double-blind, placebo-controlled trial. *Am J Sports Med* 2013;41:625-35. <https://dx.doi.org/10.1177/0363546512472975>
- Latham SK, Smith TO. The diagnostic test accuracy of ultrasound for the detection of lateral epicondylitis: a systematic review and meta-analysis. *Orthop Traumatol Surg Res* 2014;100:281-6. <https://dx.doi.org/10.1016/j.otsr.2014.01.006>
- Macdermid J. Update: the patient-rated forearm evaluation questionnaire is now the patient-rated tennis elbow evaluation. *J Hand Ther* 2005;18:407-10. <https://dx.doi.org/10.1197/j.jht.2005.07.002>
- Maffulli N, Wong J, Almekinders LC. Types and epidemiology of tendinopathy. *Clin Sports Med* 2003;22:675-92. [https://doi.org/10.1016/S0278-5919\(03\)00004-8](https://doi.org/10.1016/S0278-5919(03)00004-8)

19. McCormack RR Jr, Inman RD, Wells A, Berntsen C, Imbus HR. Prevalence of tendinitis and related disorders of the upper extremity in a manufacturing workforce. *J Rheumatol* 1990;17:958-64.
20. Mishra A, Woodall J Jr, Vieira A. Treatment of tendon and muscle using platelet-rich plasma. *Clin Sports Med* 2009;28:113-25. <https://dx.doi.org/10.1016/j.csm.2008.08.007>
21. Mizuno M, Fujisawa R, Kuboki Y. Carboxyl-terminal propeptide of type I collagen (c-propeptide) modulates the action of TGF-beta on MC3T3-E1 osteoblastic cells. *FEBS Lett* 2000;479:123-6.
22. Murtagh JE. Tennis elbow. *Aust Fam Physician* 1988;17:90-1, 94-5.
23. Nirschl RP. Elbow tendinosis/tennis elbow. *Clin Sports Med* 1992;11:851-70.
24. Nirschl RP, Ashman ES. Elbow tendinopathy: tennis elbow. *Clin Sports Med* 2003;22:813-36. [https://doi.org/10.1016/S0278-5919\(03\)00051-6](https://doi.org/10.1016/S0278-5919(03)00051-6)
25. Nirschl RP, Pettrone FA. Tennis elbow. The surgical treatment of lateral epicondylitis. *J Bone Joint Surg Am* 1979;61:832-9.
26. Ozturan KE, Yucel I, Kacici H, Guven M, Sungur I. Autologous blood and corticosteroid injection and extracorporeal shock wave therapy in the treatment of lateral epicondylitis. *Orthopedics* 2010;33:84-91. <https://dx.doi.org/10.3928/01477447-20100104-09>
27. Pammer J, Weninger W, Tschachler E. Human keratinocytes express cellular prion-related protein in vitro and during inflammatory skin diseases. *Am J Pathol* 1998;153:1353-8.
28. Peerbooms JC, Sluimer J, Bruijn DJ, Gosens T. Positive effect of an autologous platelet concentrate in lateral epicondylitis in a double-blind randomized controlled trial: platelet-rich plasma versus corticosteroid injection with a 1-year follow-up. *Am J Sports Med* 2010;38:255-62. <https://dx.doi.org/10.1177/0363546509355445>
29. Pollack SV. Silicone, fibrel, and collagen implantation for facial lines and wrinkles. *J Dermatol Surg Oncol* 1990;16:957-61.
30. Poltawski L, Watson T. Measuring clinically important change with the Patient-rated Tennis Elbow Evaluation. *Hand Ther* 2011;16:52-7. <https://doi.org/10.1258/ht.2011.011013>
31. Sampson S, Gerhardt M, Mandelbaum B. Platelet rich plasma injection grafts for musculoskeletal injuries: a review. *Curr Rev Musculoskelet Med* 2008;1:165-74. <https://dx.doi.org/10.1007/s12178-008-9032-5>
32. Shilo S, Roth S, Amzel T, Harel-Adar T, Tamir E, Grynspan F, et al. Cutaneous wound healing after treatment with plant-derived human recombinant collagen flowable gel. *Tissue Eng Part A* 2013;19:1519-26. <https://dx.doi.org/10.1089/ten.TEA.2012.0345>
33. Shiri R, Viikari-Juntura E, Varonen H, Heliövaara M. Prevalence and determinants of lateral and medial epicondylitis: a population study. *Am J Epidemiol* 2006;164:1065-74. <https://dx.doi.org/10.1093/aje/kwj325>
34. Shoseyov O, Posen Y, Grynspan F. Human recombinant type I collagen produced in plants. *Tissue Eng Part A* 2013;19:1527-33. <https://dx.doi.org/10.1089/ten.TEA.2012.0347>
35. Stein H, Wilensky M, Tsafir Y, Rosenthal M, Amir R, Avraham T, et al. Production of bioactive, post-translationally modified, heterotrimeric, human recombinant type-I collagen in transgenic tobacco. *Biomacromolecules* 2009;10:2640-5. <https://dx.doi.org/10.1021/bm900571b>
36. Tohidnezhad M, Varoga D, Wruck CJ, Brandenburg LO, Seekamp A, Shakibaei M, et al. Platelet-released growth factors can accelerate tenocyte proliferation and activate the anti-oxidant response element. *Histochem Cell Biol* 2011;135:453-60. <https://dx.doi.org/10.1007/s00418-011-0808-0>
37. Torp-Pedersen TE, Torp-Pedersen ST, Qvistgaard E, Bliddal H. Effect of glucocorticosteroid injections in tennis elbow verified on colour Doppler ultrasonography: evidence of inflammation. *Br J Sports Med* 2008;42:978-82. <https://dx.doi.org/10.1136/bjism.2007.041285>
38. Tosti R, Jennings J, Sowards JM. Lateral epicondylitis of the elbow. *Am J Med* 2013;126:357.e1-6. <https://dx.doi.org/10.1136/bjism.2007.041285>
39. Tsay RC, Vo J, Burke A, Eisig SB, Lu HH, Landesberg R. Differential growth factor retention by platelet-rich plasma composites. *J Oral Maxillofac Surg* 2005;63:521-8. <https://dx.doi.org/10.1016/j.joms.2004.09.012>
40. Viikari-Juntura E, Kurppa K, Kuosma E, Huuskonen M, Kuorinka I, Ketola R, et al. Prevalence of epicondylitis and elbow pain in the meat-processing industry. *Scand J Work Environ Health* 1991;17:38-45.
41. Ware J Jr, Kosinski M, Keller SD. A 12-Item Short-Form Health Survey: construction of scales and preliminary tests of reliability and validity. *Med Care* 1996;34:220-33.
42. Wolf JM, Ozer K, Scott F, Gordon MJ, Williams AE. Comparison of autologous blood, corticosteroid, and saline injection in the treatment of lateral epicondylitis: a prospective, randomized, controlled multicenter study. *J Hand Surg Am* 2011;36:1269-72. <https://dx.doi.org/10.1016/j.jhssa.2011.05.014>